

THE OZONE THERAPY AS PREVENTION OF AGEING OF THE LYMPH NODE

O.V. Gorchakova

*Institute of Clinical and Experimental Lymphology of SB RAMS,
Novosibirsk, Russia*

ABSTRACT — Morphologic and functional characteristics of lymph node of animals of old age after ozone correction are described in the article. The signs of aging of lymphoid tissue namely sclerosis, changes of cytology and area of structural and functional zones of lymph node responsible for drainage and immunity become clearly with age. We show that structural and immune reaction of zones of lymph node is modulated and sinus system of lymph node is optimized after ozone application. It is the base for using ozone therapy for improvement of immune and drainage functions of lymph node in the old organism.

KEYWORDS — lymph node, gerontology, ozone therapy

On the base of data of new studies it is clear that the average length of human life is increased but health isn't improved [14, 15]. This tendency is increased by diseases connecting with the age and being the main reason of the death. Moreover lymphatic system in pathogenesis is also connected with this tendency. Changes of lymphatic system disturb the processes of detoxication in lymphatic region [7, 9, 11]. So study of changes in regional lymph node is very important for understanding of pathogenesis and sanogenesis and also for search of effective methods to become longer age useful for active and creative human life [2, 9–11].

In this connection the most interested method is ozone therapy because of positive influence on organism [6, 8, 9]. But lymphatic component of the action of ozone therapy isn't studied yet. So it is necessary to give scientific base for using ozone therapy to inhibit aging lymphoid and lymphatic systems. The results of the study have practical meaning for optimal rehabilitation in elder and old patients.

The aim of the present work is to study structural and functional reaction of lymph nodes of old rats in reply to ozone therapy.

METHOD

Experiment with animals was made on the base of the principles of biological ethics, laboratory practice (GLP), "International recommendation for carrying out of medical and biological studies with animals"



PhD, research worker
of Laboratory of Institute
of clinical and experimental
Lymphology SB RAMS
Novosibirsk, Russia,
e-mail: gorchak@soramn.ru

(1985) and order of Ministry of Health of Russian Federation № 267 from 19.06.2003. 160 white rats-male of Wistar breed of different ages (young rats were 3–5 months, old rats were 12–15 months) [4] in the conditions of Novosibirsk city have been used in experiment. Animals were given extruded mixed feed PK-120-1 and unlimited quantity of water. Ozone application with ozonized olive oil during 15-20 minutes every other day was made on the region of lymph accumulation of groin lymph nodules, course was 14 applications. Ozone saturation of olive oil was made with apparatus OP1-M with device for ozonization. Lymph therapy with applications show positive results without side effects [3], and this result is a base for using applications in medicine practice. Groin lymph nodes were studied with histological method [1, 5, 12, 15]. Pieces of lymph nodes were fixed in 10% neutral formalin, processed and embedded with paraffin. Histological slices were made and stained with hematoxylin and eosin, azure and eosin, toluidine blue. Morphometric analysis of structural components of lymph node was made with morphometric test grid [1] which was put on the slice of lymph node. The number of nodes or intersections of grid on the slice totally and on each structural component separately were counted and recounted in percents. Obtained data were statistically processed with program of statistical analysis StatPlus Pro 2009, AnalystSoft Inc.

RESULTS AND DISCUSSION

Lymphatic nodes are the part of lymphatic stream and change with age because of sclerotic process. This process is accompanied with thickening of capsule,

appearing of connective tissue around vessels and sinuses in lymphoid parenchyma of lymphatic nodes of old animals. At the same time subcapsular sclerosis parallel to boundary sinus of peripheral cortex is localized (Fig. 1). We think that subcapsular sclerosis is a result of unfavorable ecologic environment and makes difficult to pass lymph in compartment of lymph node. Area of structural and functional zones of lymph node responsible for cellular and humoral immunity is changed in lymphatic node of old rats (Table 1).

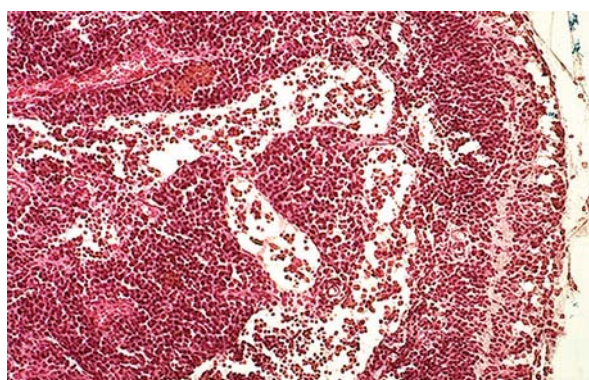


Fig. 1. Elements of subcapsular sclerosis in cortical plateau, extended sinuses of lymph node. Old rats. Hematoxylin and eosin stain. Magnification: ocular 7, objective 10.

in periphery or in form of separate strip but structure of paracortex is locally impoverished with cells. Insufficiency of cellular component of immunity of lymphatic node of old rats is formed. Medullar sinuses of lymphatic nodes of old rats looked as extended formations running through tissue of lymph node (Fig. 1). Medullar sinus size was increased in 2,3 times (Table 1).

These changes show disproportion between inflow of lymph in lymph node and outflow of lymph from lymph node. Extended sinuses are structural prerequisite for slowing down of flow of lymph, lowering of drainage and detoxication functions and lowering of immune functions of lymph node. Functionally lymph node is in the compensation state that is the sign of unfavorable ecologic environment, thus lymph node is an indicator of external and internal environment [7, 15].

Ozone therapy may be prophylactic of early aging of lymphoid and lymphatic systems. Transdermal effect of ozone application contributes the changing of structural and functional zones of lymph node changed with age and environment. It was marked statistically reliable decrease of area of cortical plateau in 1,7 times, area of paracortex in 1,5 times, area of medullar sinus in 1,8 times, and lowered proliferative activity of germinative centers of lymphoid nodules on

Table 1. Area of structural and functional zones of lymphatic node in different ages and after ozone application, %

Structures of lymph node	Young animals (3–5 months)		Old animals (12–15 months)	
	Without correction	Ozone application	Without correction	Ozone application
	1	2	3	4
Capsule	1,16±0,09	0,98±0,08	1,62±0,07*	1,79±0,10*
Subcapsular sinus	0,57±0,07	0,56±0,06	0,41±0,04	0,49±0,03
Cortical plateau	1,20±0,09	1,53±0,08°	1,90±0,08°*	1,12±0,08°*
Lymph nodule without germinative center	1,16±0,06	1,25±0,06	1,24±0,08	1,35±0,06
Lymph nodule with germinative center	1,61±0,17	1,58±0,17	1,37±0,12°*	1,21±0,08
Paracortex	7,14±0,67	5,92±0,53°	8,94±0,49	5,77±0,38°
Medullar cords	5,20±0,32	4,11±0,27°	5,02±0,34	4,88±0,25
Medullar sinus	1,30±0,12	1,63±0,10°	2,94±0,20*	1,59±0,17°
Total area	19,35±1,03	17,55±1,11	23,44±1,35	18,20±0,68°

Note: ° P_{1-2,3-4} < 0,05; * P_{1-3,2-4} < 0,05

Cortical plateau of lymph node of old rats is increased in 1,6 times in comparison with that of young rats. Area of lymphoid nodules particularly having germinative centers is decreased that is a sign of decreased proliferative process in old lymph node. Paracortex maintains compact arrangement of lymphoid cells or

the side of ozone application of lymph node of old rats (Fig. 2). Peculiarities of effect of ozone application are the increase of area of cortical plateau and maintained high lymphopoiesis in germinative centers of young rats and the decrease of cortical plateau, paracortex and lowered lymphopoiesis in germinative centers of

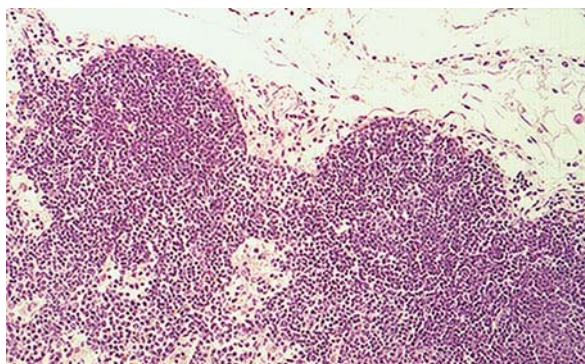


Fig. 2. Lymphoid nodules (follicles) linked with bridge of cortical plateau. Cortical shunts. Decrease of size of cortical plateau and sinuses. Old rats. Ozone application. Hematoxylin and eosin stain. Magnification: ocular 7, objective 10.

old rats. The most of structural and functional zones of groin lymph nodes were changed in similar way and in young and in old rats as a response on ozone therapy (Table 1). Optimization of sinus system of lymph node is a result of ozone application that is very important for drainage and detoxication function of lymph node under the unfavorable environment. Modulating effect of ozone therapy namely decrease of high indexes and increase of low indexes of area of structural and functional zones of lymph node may be supposed on the base of character of change of area of cortical plateau in young and old rats. This regularity is appeared for the most of structural and functional zones of lymph node of old rats after ozone application (Table 1).

CONCLUSION

Structure of lymph node of old rats have signs which reflect total process of aging and become more clearly under the unfavorable environmental conditions. It is related to connective tissue component and lowered lymphopoiesis. Ozone correction cause different in intensity structural response of lymph node and have modulating effect. Old rats show the increase of immune potential and drainage function of lymph node. This conclusion is based on character of changes of structural and functional zones of lymph node. This fact defines expediency of using of ozone therapy in old age in program of endoecologic rehabilitation and measures against aging under the unfavorable environment conditions.

REFERENCES

1. **AVTANDILOV G.G.** Medical morphometry / G.G. Avtandilov. – Moscow: Medicine, 1990. – 384 p. (in Russia).
2. **ALTMAN D.S.** Rate of aging and indexes of immune status in participants of modern wars / D.S. Altman, S.N. Teplova, N.G. Kochetkova [et al.] // «Gerontology and geriatrics», 2003. – № 2. – P. 195–196. (in Russia)
3. **AREFYEVA I.S.** Effective therapy of diseases spreading by sexual way under the laboratory conditions / I.S. Arefyeva, A.B. Baibakov // Thesis of III International congress «Endoecologic medicine». Republic of Cyprus., 21–28 October 2007. – Moscow: «Sherbinskaya typography», 2007. – P. 29–30. (in Russia)
4. **ARUIN L.I.** Structural peculiarities of compensatory and adaptive processes. / L.I. Aruin // Monograph: Common pathology. – Moscow: Medicine, 1990. – P. 233–290. (in Russia)
5. **BELYANIN V.L.** Diagnostics of reactive hyperplasia of lymph nodes / B.L. Belyanin, D.E. Tsuplakov. – Sankt-Peterburg–Kazan, 1999. – 328 p. (in Russia)
6. **GORCHAKOV V.N.** Phytolymphonutriciology / V.N. Gorchakov, E.B. Saranchina, E.D. Anohina // «Practical phytotherapy» 2002. – N 2. – P. 6–9. (in Russia)
7. **KONENKOV V.I.** Lymphology / V.I. Konenkov, Yu.I. Borodin, M.S. Lyubarskii – Novosibirsk: Publishing House «Manuskript», 2012. – 1179 p. (in Russia)
8. **KULIKOV A.G.** Ozone therapy: microhemodynamic effects // Physiotherapy, balneology and rehabilitation, 2012. – N 3. – P. 3–8. (in Russia)
9. **LEVIN YU.M.** New in endoecologic medicine. New level of medical mentality and effective therapy / Yu.M. Levin. – Moscow: «Sherbinskaya typography», 2006. – 200 p. (in Russia)
10. **TKACHENKO N.M.** Substitution hormone therapy for aging female organism / N.M. Tkachenko, L.M. Ilyina // «Gerontology and geriatrics». – Moscow, 2003. – Vol. 2. – P. 149–153. (in Russia)
11. **TOROPOVA S.G.** Peculiarities of system of pericellular humoral transport under aging // «Gerontology and geriatrics». – Moscow, 2003. – Vol. 2. – P. 90–94. (in Russia)
12. **COTTIER H.** Proposals for standards of describing histology of human lymph node connective with immunologic function / H. Cottier, J. Turk, L. Sobin // Bulletin WHO, 1973. – P.372–377. (in Russia)
13. **CRIMMINS E.M.** Mortality and morbidity trends: is there compression of morbidity? / E.M. Crimmins, H. Beltran-Sanchez // Journals of Gerontology Series B-Psychological Sciences and Social Sciences, 2011. – V. 66(1). – P.75–86.
14. **DENCLA W.D.** Interactions between age and neuroendocrine and immune system // Exp. Pathol., 1979. – Vol. 17. – P.538–545.
15. **ISAACSON P.G.** Normal structure and function of lymph nodes // In: Oxford Textbook of Pathology (ed. J.O'D. McGee, P.G. Isaacson, N.A. Wright). – Oxf. Univ. Press, 1992. – P.1745–1756.