

CONNECTION BETWEEN CLINICAL AND RADIOLOGICAL TORQUE OF MEDIAL INCISORS AT PHYSIOLOGICAL OCCLUSION

T.D. Dmitrienko¹, D.A. Domenyuk², M.P. Porfyriadis²,
A.G. Arutyunova³, A.A. Kondratyuk⁴, R.S. Subbotin⁴

Article history:

Received 9 February 2019

Received in revised form 5 March 2019

Accepted 10 March 2019

¹ Department of Dentistry, Pyatigorsk Medical-Pharmaceutical Institute (Branch of Volgograd State Medical University, Ministry of Healthcare, Russian Federation, 11, pr. Kalinina, Pyatigorsk-32, Stavropol Region, Russia 357532. E-mail: s.v.dmitrienko@pmedpharm.ru, tel: +7 8793 32 4474

² Department of general practice dentistry and child dentistry, Stavropol State Medical University, Ministry of Healthcare of Russian Federation, 310, Mira Street, Stavropol, Russia 355017, E-mail: domenyukda@mail.ru, tel: +7 918 870 1205

³ Department of Pediatric Dentistry, Orthodontics and Maxillofacial Surgery, Kuban State Medical University, Ministry of Healthcare of Russian Federation, M. Sedina str., 4, Krasnodar, Russia, 350063, E-mail: kaf-detstom@yandex.ru, tel: +7 861 268 0210

⁴ Department of pediatric dentistry and orthodontics Saint-Petersburg State Pediatric Medical University, Saint-Petersburg, Russia, st. Lithuanian, 2, 194100. E-mail: spb@gpma.ru, tel: +7 812 295 0646

INTRODUCTION

Lifetime X-ray and morphological diagnostics represent the major tools of research and applied value, which help solve numerous diagnostic issues faced by a number of specialists involved in public healthcare [1–9].

The growing interest taken currently in dentition morphometric studies is due to the systematization and specification of the accumulated data, which allows clinicians (dentists, maxillofacial surgeons) to compare the external maxillofacial parameters with the person's internal structural features not only in the normal status, yet also in case of pathological conditions. Besides, the effectiveness of the introduced advanced dental treatment should rely not only on improved equipment and materials, but also on better diagnostic technologies in view of the fundamental topographic anatomy knowledge, which would allow an individual approach to each case, as well as help achieve consistent and stable positive outcomes [10–15].

The individual position of the incisors has been in the focus of many researchers' works. There is plenty of detailed data regarding incisors torque, described in view of the dental and gnathic face types, and follow-

ABSTRACT — AIM. To determine the link between the clinical and radiological torque of the medial incisors in cases with physiological occlusion.

Materials and methods. A measurement of the clinical torque values was performed (whereas the torque is defined as the deviation of the tooth crown vestibular surface from the occlusal plane) in 98 people with physiological occlusion and a full set of permanent teeth. When measuring the clinical incisor torque, three methods were employed. The first method allowed studying teeth torque in relation to the occlusal plane on the cast jaw models using the Arco-Zet equipment (by Scheu Dental GmbH). The second method implied using a modified protractor, where the moving part was oriented in relation to the occlusal plane. The third method we used involved analyzing data from telerradiography and cone-beam tomograms obtained with the PaX-i3D SC digital panoramic X-ray unit (VATECH Global), which were marked with linear and angular reference points. The patients were divided into three groups depending on the incisors location: Group 1 included patients with the mesotrusive incisors location; Group 2 were patients with physiological protrusion of the incisors and a decrease in the interincisal angle, with Group 3 including patients with physiological retrusion of incisors. RESULTS. Regardless of the type of dental arches and the vestibular lingual inclination of the incisors, the average difference between the clinical and the radiological incisor torque values is 26°, which can be used in clinical orthodontics to develop a treatment tactics and its effectiveness in people with various gnathic and dental types as well as with various dental arches.

CONCLUSION. All methods used for measuring the teeth inclination angles in the vestibular lingual direction can be employed both in the applied and in the clinical aspect. Identifying the permanent teeth torque through cast models of dentition morphometry and through using special equipment, takes a lot of effort, time, at the same time being subject to potential measurement errors. The methods implying analysis of cone-beam computed tomography images feature high-tech reliance, precision, whereas the reproductive capacity and interpretation of the results allows using the available angular and linear parameters for evaluating the effectiveness of the respective orthodontic procedures through all the stages of treatment.

KEYWORDS — medial incisor torque, cone-beam computed tomography, protrusion and retrusion of incisors, interincisal angle, physiological occlusion.

ing the contemporary classifications of the face and dental arch types. The obtained data has shaped the basis for braces design concerning the arc equipment [16–19].

There has been a dependence identified between the inclination of the front incisors and the Schwartz facial angle (ANB), while a 1-degree change in the ANB angle results in a 1-degree or a 1-mm change in the front incisor inclination [20]. The features of the lower jaw incisors location have made the basis for adopting extraction methods in orthodontic treatment offered in case of disturbed dental arch shape and size. Following the “teeth shift” concept in orthodontics, patients with class I bite anomaly are to have their teeth removed with a deviation from the midline, crowding, bimaxillary protrusion, vertical mismatch, distal bite (overjet), and incisor inclination increase [21–26]. Currently, the orthodontic treatment planning is done reasoning from the position of the upper incisors, and not the molars or the lower jaw incisors. Given that, when planning mechanical teeth shift, some clinicians recommend placing the incisors in an ideal position to further restore the occlusal match of the remaining teeth [27–30].

Other experts offer proof to the fact that in case there is no way to provide an ideal position for the incisors, they can be placed in a “non-ideal”, yet acceptable one, and define this as an “optimal functional occlusion” using it as the basis. Identifying the angle of the incisors vestibular lingual inclination is a key task when developing methods for treating patients with maxillofacial issues through different age stages, including milk dentition bite. At the same time, identifying the incisors torque takes a detailed analysis since their location, as researchers show, is determined by various numerical values in relation to the major anatomical points. As a rule, in clinical orthodontics the upper incisors vestibular inclination determines their relation to the Frankfurt horizontal or spinal (maxillary) plane [31–34].

G.W. Arnett X-Ray Analysis (1999) identifies the upper incisors torque in relation to the occlusal plane and takes into account the gender dimorphism of this feature. For males, the angle is 58°, while for women it is 57° [35].

In clinical orthodontics, the teeth torque is identified from the position of the teeth vestibular surface against the occlusal plane perpendicular. Due to that, the torque values of the upper jaw medial incisors vary from 3 to 27°, and are expressed in such terms as “low”, “standard” and “high” teeth torque. However, the published research papers do not show what types of dental arches and faces are to be found in patients who are to use the specified braces. Mention to be made of

another opinion expressed by specialists noting that during physiological occlusion, the medial upper incisors torque values are determined by the gnathic and dental types of dental arches [36,37,38].

The variety of braces and ways of inclination angles’ measuring suggest the need for employing an individual approach and choice of optimal investigation to ensure diagnostic accuracy [39,40,41].

The instrumental methods that are used focus on the occlusal, Camper’s, and mandibular planes. These methods are effort- and time-consuming, while potential errors are complicated when applying morphometric landmarks, reference lines, comparing projection data, and involve varying anatomy of the examined tooth surface [42,43,44,45,46,47]. The leading role in determining the inclination angles of the incisors belongs to cone-beam computed tomography (CBCT), which offers high precision in identifying the inclination angles and the angles formed by antagonists (in particular, the interincisal angle) [48,49,50,51,52]. The reason behind this study is the lack of data available in the respective research literature focusing on the relationship between the clinical and the radiological medial incisors torque in case of physiological occlusion.

Aim of study

To identify the relationship between the clinical and the radiological medial incisors torque in case of physiological occlusion.

MATERIALS AND METHODS

The study involved 98 people with physiological occlusion and a full set of permanent teeth. The patients were divided into three groups depending on the incisors location: Group 1 included patients with mesotrusive position of the incisors where the interincisal angle was 125°–134°. The patients in Group 2 featured physiological protrusion of the incisors and a decrease in the interincisal angle (below 120°). In Group 3, the patients had an interincisal angle exceeding 145° also revealing physiological retrusion of the incisors. The telerradiography and cone-beam tomograms were obtained on a 21-section digital panoramic X-ray unit PaX-i3D SC featuring the functions of a computed tomograph and an FOV cephalostat with accessories (VATECH Global, South Korea) following the scanning protocol for Sim Plant. Processing, storage and export of the X-ray images involved the Ez Dent-iTM software, a multiplanar reconstruction and a three-dimensional (3D) reconstruction – using the Ez 3D-iTM tomograph software for 3D diagnostics; viewing the saved data with an importing option was performed using the Viewer™ software. The thickness of the tomographic section was 1 mm, the reconstruc-

tion step was 1 mm, the rotation step – 1 mm. In order to identify the occlusal plane, the radiographs had the major reference points applied on them. The distal point (hPOcP) corresponded to the location of the lower second molar distal tubercle. The front point (vPOcP) corresponded to the midpoint of the distance between the cutting edges of the incisors (Fig. 1).

The tomograms had a conditional median vertical of the medial incisor built on them and running from the incisor's cutting edge through the tooth neck middle. The obtained lines shaped an interincisal X-ray angle (Fig. 2).

Besides, tangent lines were drawn to the vestibular contour of the incisors crowns, which, at their intersection, made up an interincisal clinical angle. The reference points were those located at the cutting edge, near the vestibular contour of the crown, and at the top convexity point of the vestibular contour – on the tooth equator (Fig. 3).

The following were used as the major telerradiography points: N (Nasion) – located at the junction of the frontal and nasal bones; C (Condylion) – the top point of the articular head; Ar (Articulare) – the distal contour of the mandible articular head neck; T2 – the posterior lower nub of the mandible angle; Me (Menton) – the lowest point on the lower jaw contour, at the symphysis site. These anthropometric spots served as reference points for the construction of the Frankfurt horizontal (FH), the occlusal plane (OP) and the mandibular plane (MP). Besides, conditional median verticals were drawn through the cutting edge of the incisors and the tooth root apex, whereas the verticals served as guidelines for identifying the interincisal angle and for joining the maxillary incisal tomogram lines with the telerradiography facial skull plane (Fig. 4).

The clinical incisor torque was measured not radiographically only, yet also on cast jaw models. The jaw models were studied using a respective device by Scheu-Dental (Germany), which allowed evaluating the teeth torque relative to the occlusal plane. When manufacturing the cast models, the model base was in relation to the occlusal plane. The model was installed on a stage equipped with a level that allowed orienting the model in the horizontal plane. From the vestibular side of each model tooth, a conditional median vertical was drawn. A thin drill was used to make a hole in the crown center thus allowing the central probe of the device to be located in it, while the probe was connected to a measuring device to identify the inclination angle in°. The other research method was measurement using a modified protractor where the moving part was oriented in relation to the occlusal plane (Fig. 5).

The study outcomes were statistically processed using the SPSS 17.0 software package at a 0.05 signifi-

cance level. When performing quantitative description, the mean value (M) and the standard mean error (m) were used. The statistical processing was carried out using descriptive statistics, analysis of variance (Student's t-test), correlation analysis (Pearson and Spearman's paired correlation coefficients), and with nonparametric statistics methods (Mann-Whitney and Wilcoxon).

RESULTS AND DISCUSSION

The study results of the computed tomograms revealed that the inclination incisors angles in the vestibular lingual direction had features that depended on the dental arch type.

Table 1 shows the results of the study concerning the patients with physiological occlusion.

The results of studying the inclination of the upper medial incisors in the anterior-posterior direction (torque), which was measured by computed tomograms and jaw cast models, showed that in Group 1, with mesotrusive incisors arrangement, the magnitude of the clinical torque, determined through the deviation of the tooth crown vestibular surface from the occlusal plane, was $77.64 \pm 2.23^\circ$. The obtained values were close to the standard values of braces for the upper jaw medial incisors. At the same time, the vestibular lingual inclination of the upper medial incisors in relation to the occlusal plane was $51.52 \pm 3.57^\circ$, and was slightly below the values once set by G.W. Arnett (1999). The difference between the clinical and the radiographic torque at the upper medial incisors was $26.12 \pm 2.11^\circ$. The clinical torque of the mandibular medial incisor, determined through the deviation of the tooth crown vestibular surface from the occlusal plane, was $89.33 \pm 0.45^\circ$. The obtained values were close to the standard values describing the braces for the mandibular medial incisors. At the same time, the vestibular lingual inclination of the lower medial incisors in relation to the occlusal plane was $62.75 \pm 2.33^\circ$. The size of the interincisal angle, shaped by the conditional median verticals of the antagonists, in Group 1 was $134.21 \pm 3.81^\circ$. The angle made by the tangent lines to the vestibular surfaces of the antagonists was $169.34 \pm 5.94^\circ$.

In Group 2 (with protrusive position of incisors) the clinical torque was $69.56 \pm 3.61^\circ$. The obtained values were close to those of braces with a "high" torque for the upper jaw medial incisors. At the same time, the vestibular lingual inclination of the upper medial incisors in relation to the occlusal plane was $44.11 \pm 3.57^\circ$ and was significantly below the values identified in Group 1, as well as the values established by G.W. Arnett (1999). The difference in the clinical and in the

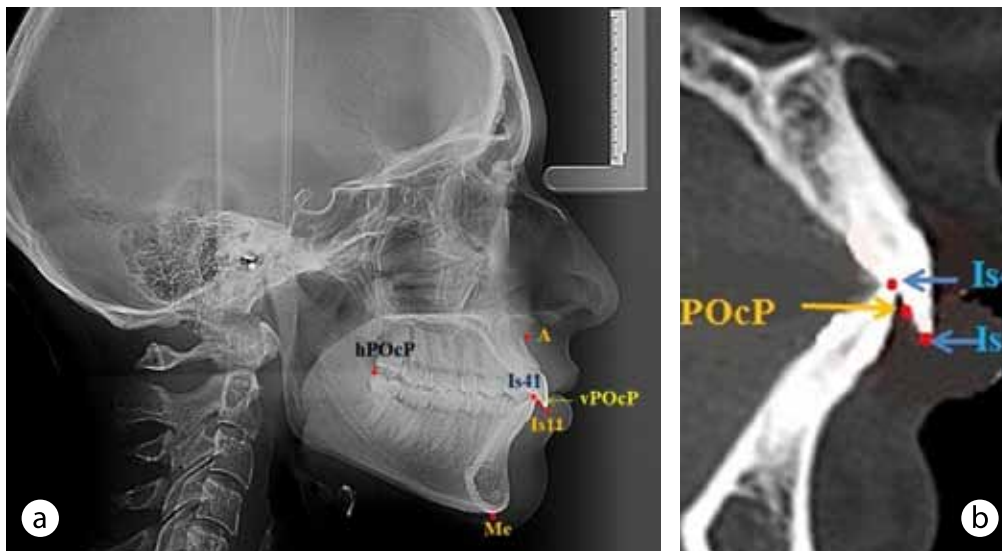


Fig. 1. Anatomical landmarks on a telegentogram (a) and a cone-beam tomogram (b) for constructing an occlusal plane

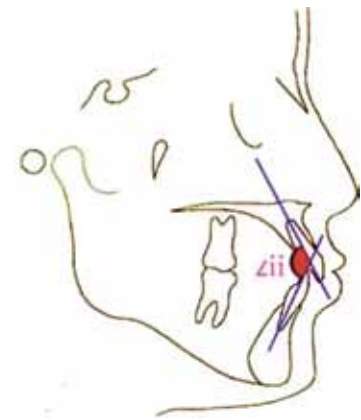


Fig. 2. Determination of cutter angle (Lii)

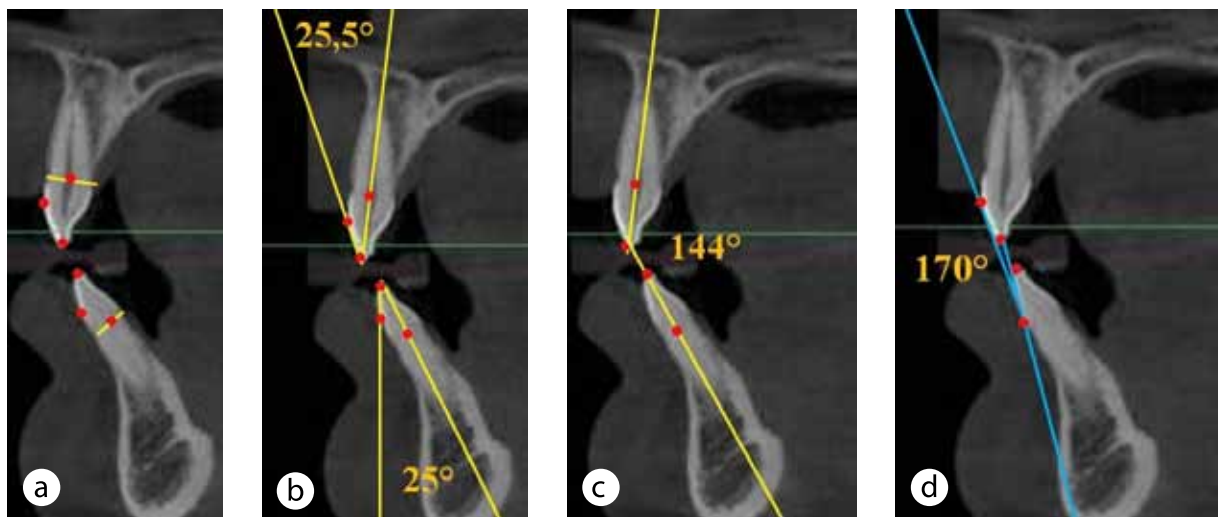


Fig. 3. Methods for studying inclination angles of incisors on tomograms: (a) main odontometric points; b — measurement of the difference in position of the reference lines; c — measurement of the intercutaneous radiological angle; d — measurement of the intercutaneous clinical angle

radiographic torque in the upper medial incisors was $26.12 \pm 2.11^\circ$. The clinical torque of the mandibular medial incisor, determined through the deviation of the tooth crown vestibular surface from the occlusal plane, was $86.03 \pm 1.14^\circ$. The obtained values were close to those for braces with a “high” torque for the mandibular medial incisors. At the same time, the vestibular lingual inclination of the lower medial incisors in relation to the occlusal plane was $60.89 \pm 1.87^\circ$. The size of the interincisal angle, shaped by the conditional median verticals of the antagonists in Group 2 was

$118.31 \pm 4.45^\circ$. At the same time, the angle made by the tangent lines to the vestibular surfaces of the antagonists was $201.07 \pm 6.27^\circ$.

In Group 3 patients with incisor retrusion, the clinical torque was $84.27 \pm 2.25^\circ$. The obtained values were close to those for braces with a “low” torque for the medial upper jaw incisors. At the same time, the vestibular lingual inclination of the upper medial incisors in relation to the occlusal plane was $57.85 \pm 2.89^\circ$ and was close to the values observed in Group 1 patients, as well as the values set by G.W. Arnett

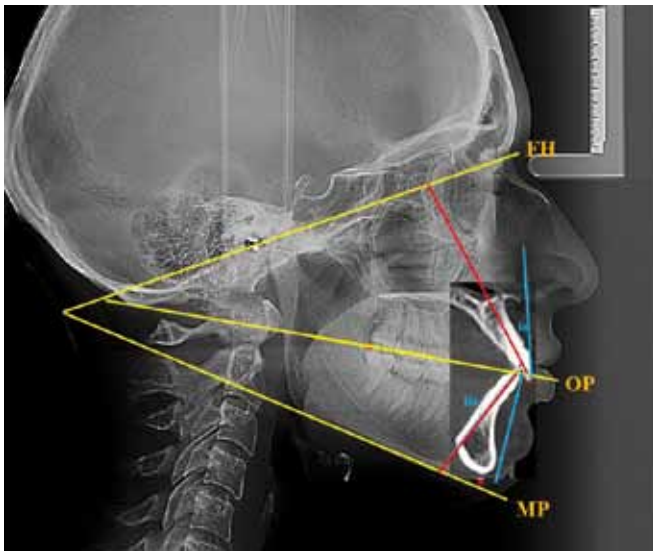


Fig. 4. The combination of teleroenogram and cone-beam tomogram with marked reference lines

Fig. 6 shows the major values of the incisors torque in the patients belonging to the groups in question.

Integrating the obtained data, we can state that visualization of the structures of the dental system and their topographic interconnection in high spatial resolution creates ground for constructing idealized, averaged models, as well as models that provide a maximum reproduction of the patient's individual features not only in view of the spatial orientation (geometry), yet also of the structure (morphology) of tissues, opening up newer opportunities in biomechanical analysis of human bone joints.

CONCLUSIONS

1. The methods employed for measuring the inclination angles of the upper and lower jaws teeth, as well as for identifying the inclination angles of the antagonizing teeth are diag-

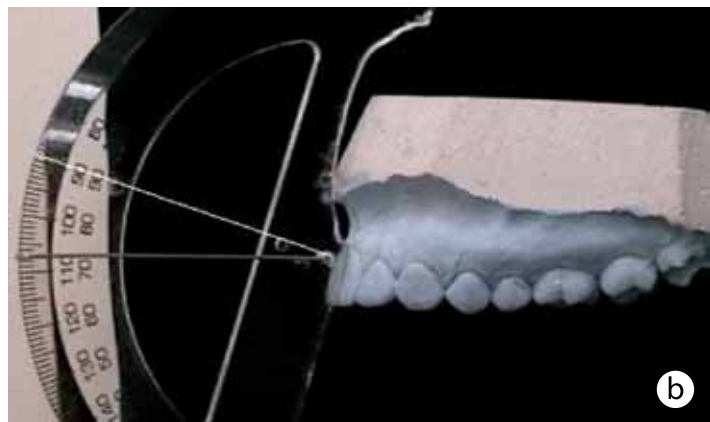
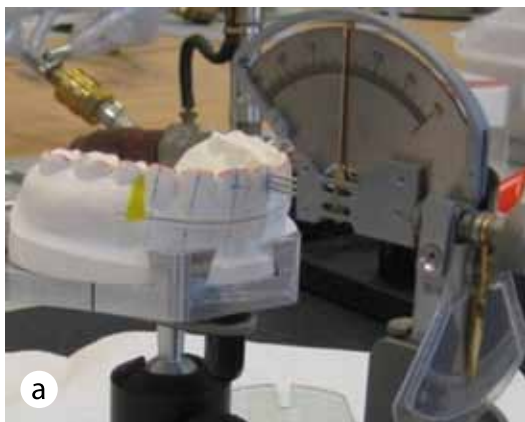

Fig. 5. Methods for the study of the clinical incisor of the incisors on a device made by Scheu-Dental (a), and using a protractor (b)

(1999). The difference between the clinical and the radiographic torque in the upper medial incisors was $26.12 \pm 2.11^\circ$. The clinical torque of the mandibular medial incisor, identified through the deviation of the tooth crown vestibular surface from the occlusal plane, was $92.09 \pm 1.16^\circ$. The obtained values were close to the standard values of the braces for the mandibular medial incisors. During that, the vestibular lingual inclination of the lower medial incisors in relation to the occlusal plane was $67.08 \pm 1.54^\circ$. The size of the interincisal angle, shaped by the conditional median verticals of the antagonists, in Group 1 was $149.89 \pm 4.24^\circ$. The angle made by the tangent lines to the antagonists vestibular surfaces was $180.26 \pm 4.12^\circ$.

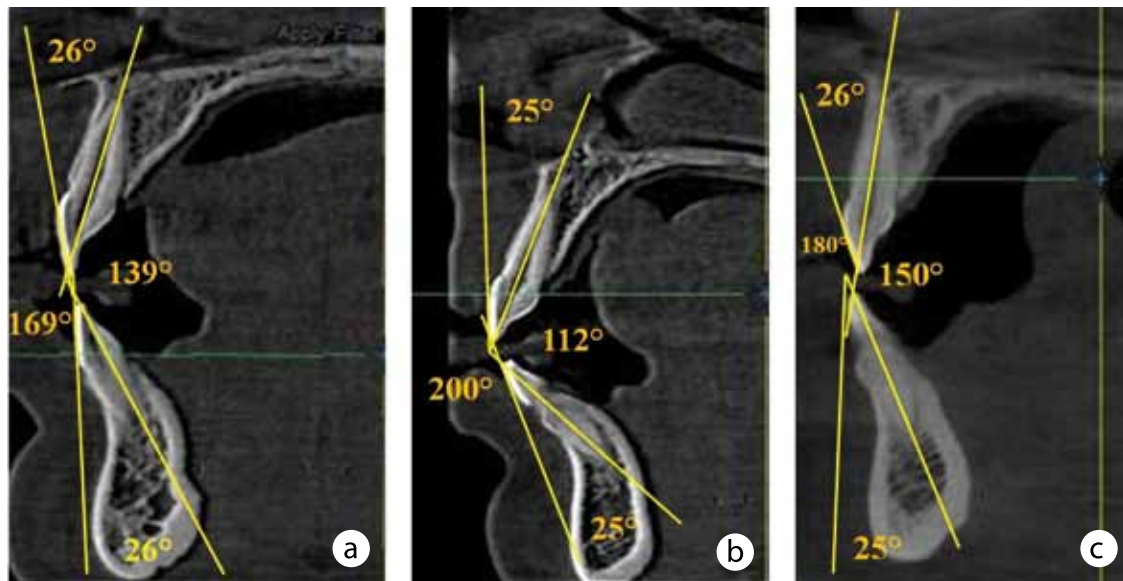
nostically valuable, offer reliable data, and can be used not only to describe the physiological occlusion, but also to evaluate the effectiveness of the orthodontic treatment given to patients with dentofacial pathologies.

2. Regardless of the dental arch type and the incisors vestibular lingual inclination, the difference between the clinical and the radiological incisors torque was an average of 26° , which can be used in clinical orthodontics to design the treatment tactics and evaluate its effectiveness in people with different gnathic and dental types of face and dental arches.

3. If introduced into clinical orthodontics, the obtained results involving the reference values limits

Table 1. The inclination angle of incisors in patients of the studied groups, ($M \pm m$), ($p \leq 0,05$)

Parameters	The inclination angle of incisors (in degrees):					
	Clinical angle (people)			X-ray angle (people)		
	1 group	2 group	3 group	1 group	2 group	3 group
Tork top cutter	77,64±2,23	69,56±3,61	84,27±2,25	51,52± 3,47	44,11± 3,57	57,85±2,89
Tork lower tool	89,33±0,45	86,03±1,14	92,09±1,16	62,75±2,33	60,89±1,87	67,08±1,54
Cutter angle	169,34±5,94	201,07±6,27	180,26±4,12	134,21±3,81	118,33±4,45	149,89±4,24

**Fig. 6.** Basic values of the incisor of the incisors during mesotrusion (a), protrusion (b) and retrusion (c)

and the confidence intervals of inclination angles for the upper and lower jaw teeth, as well as the inclination of the antagonizing teeth, would allow reducing the time spent on early diagnostics as well as improve the efficiency of monitoring the orthodontic correction outcomes.

4. In order to prevent the temporomandibular joint dysfunction during orthodontic treatment, special attention should be paid to the torque of the medial and lateral upper incisors, which act as guides through the mandible anterior movement.

5. Improving the available methods used to diagnose dental anomalies resulted in high-tech, high-precision, computerized methods employed to measure the maxillofacial area structures, which, when introduced, would allow not only minimizing the errors associated with instrumental measurement techniques, but also achieving better functional aesthetic outcomes due to a higher predictability of orthodontic treatment.

6. Based on the anthropometric and clinical diagnostic studies outcomes, the localization of the

standard (classical) and additional morphometric points in axial, frontal, sagittal reformats has been refined. Specifying the spatial location (topography) of the anatomical landmarks through cone-beam computed tomography allows increasing the reliability and the accessibility of measurements, standardizing anthropometric studies of human craniofacial structures, conducting a detailed assessment of their shape, as well as getting more significant amount of reliable data with high-precision dimensional features.

7. Cone-beam computed tomography employed for studying the craniofacial structures, expands significantly the current understanding of the variability of the “anatomical norm”, which is determined by individual-typological variability, gender differences, age-related changes, area of residence, etc., thus making it possible to obtain data that is of importance for personalized medicine.

8. Systematizing the data obtained through a comprehensive assessment of the individual anatomical variability of the craniofacial structures in the axial,

frontal, and sagittal planes, allows us to expand significantly the current pool of knowledge to further ensure better interdisciplinary cooperation involving areas like medical craniology, dentistry, radiology, maxillofacial surgery, neurosurgery, otolaryngology, anatomic pathology, and forensic medicine.

REFERENCES

1. **DOMENYUK D., PORFYRIADIS M., DMITRIENKO S.** Major telerehthengogram indicators in people with various growth types of facial area. *Archiv EuroMedica*, 2018; Vol. 8; 1: 19-24.
2. **DMITRIENKO S.V., LEPILIN A.V., FOMIN I.V., DOMENYUK D.A., DAVYDOV B.N.** Study of morphology, methods of comparison of tooth and alveolar arcs by results of anthropometry and cellular-beam computer tomography (Part I). *The Dental Institute*. 2018; 79(2): 68-72. (In Russ.).
3. **DOMENYUK D.A., KONNOV V.V., PICHUGINA E.N., ANFINOGENOVA O.I., GONCHARENKO A.N., PUSHKIN S.V.** Microcomputed tomography in qualitative and quantitative evaluation of dental enamel demineralization. *Entomology and Applied Science Letters*. 2018; 5(4): 72-83.
4. **PORFYRIADIS M.P., DOMENYUK D.A., DAVYDOV B.N., VEDESHINA E.G., DMITRIENKO S.V.** Features of tactics and principles orthodontic treatment of patients with dental arches asymmetry caused by different amounts of antimeres (Part I). *The Dental Institute*. 2017; 77(4): 64-68. (In Russ.).
5. **SHKARIN V., DOMENYUK D., LEPILIN A., FOMIN I., DMITRIENKO S.** Odontometric indices fluctuation in people with physiological occlusion. *Archiv EuroMedica*, 2018; Vol. 8; 1: 12-18.
6. **BORODINA V.A., DOMENYUK D.A., VEISGEIM L.D., DMITRIENKO S.V.** Biometry of permanent occlusion dental arches - comparison algorithm for real and design indicators. *Archiv EuroMedica*, 2018; Vol. 8; 1: 25-26.
7. **KOROBKEEV A.A., DOMENYUK D.A., SHKARIN V.V., DMITRIENKO S.V.** Types of facial heart depth in physiological occlusion. *Medical news of North Caucasus*. 2018. – Vol. 13. – № 4. – P. 627-630. (In Russ., English abstract). DOI – <https://doi.org/10.14300/mnnc.2018.13122>
8. **PORFYRIADIS M.P., DOMENYUK D.A., DAVYDOV B.N., DMITRIENKO S.V., BUDAYCHIEV G.M.-A.** Variability of cephalometric indices in men and women with mesocephalic form of the head and various constitutional types of face (Part II). *The Dental Institute*. 2018; 79(2): 82-85. (In Russ.).
9. **DMITRIENKO S.V., DOMENYUK D.A.** Dentoalveolar specifics in children with cleft palate during primary occlusion period. *Archiv EuroMedica*, 2018; Vol. 8; 1: 33-34.
10. **DOMENYUK D.A., LEPILIN A.V., FOMIN I.V., DMITRIENKO S.V.** Improving odontometric diagnostics at jaw stone model examination. *Archiv EuroMedica*, 2018; Vol. 8; 1: 34-35.
11. **PORFYRIADIS M.P., DMITRIENKO S.V., DOMENYUK D.A., BUDAICHIEV G.M.A.** Mathematic simulation for upper dental arch in primary teeth occlusion. *Archiv EuroMedica*, 2018; Vol. 8; 1: 36-37.
12. **LEPILIN A.V., FOMIN I.V., DOMENYUK D.A., DMITRIENKO S.V.** Diagnostic value of cephalometric parameters at graphic reproduction of tooth dental arches in primary teeth occlusion. *Archiv EuroMedica*, 2018; Vol. 8; 1: 37-38.
13. **SHKARIN V.V., DAVYDOV B.N., DOMENYUK D.A., DMITRIENKO S.V.** Non-removable arch orthodontic appliances for treating children with congenital maxillofacial pathologies – efficiency evaluation. *Archiv EuroMedica*, 2018; Vol. 8; 1: 97-98.
14. **PORFYRIADIS M.P., DOMENYUK D.A., DAVYDOV B.N., VEDESHINA E.G., DMITRIENKO S.V.** Features of tactics and principles orthodontic treatment of patients with dental arches asymmetry caused by different amounts of antimeres (Part II). *The Dental Institute*. 2018; 78(1): 56-61. (In Russ.).
15. **DMITRIENKO S.V., DOMENYUK D.A., KOCHKONYAN A.S., KARSLIEVA A.G., DMITRIENKO D.S.** Interrelation between sagittal and transversal sizes in form variations of maxillary dental arches // *Archiv EuroMedica*, 2014. – Vol. 4. – № 2. – P. 10-13.
16. **GORELIK E.V., DMITRIENKO S.V., IZMAYLOVA T.I., KRAYUSHKIN A.I.** Features of the craniofacial complex in different age periods // *Morphology*. – 2006. – № 4. – P. 39.
17. **DMITRIENKO S.V., DOMENYUK D.A., VEDESHINA E.G.** Shape individualization in lower dental arches drawn on basic morphometric features // *Archiv EuroMedica*, 2015. – Vol. 5. – № 1. – P. 11-15.
18. **PORFYRIADIS M.P., DOMENYUK D.A., DAVYDOV B.N., DMITRIENKO S.V., BUDAYCHIEV G.M.-A.** Variability of cephalometric indices in men and women with mesocephalic form of the head and various constitutional types of face (Part I). *The Dental Institute*. 2018; 78(1): 70-73. (In Russ.).
19. **DOMENYUK D.A., SHKARIN V.V., PORFYRIADIS M.P., DMITRIENKO D.S., DMITRIENKO S.V.** Classification of facial types in view of gnathology // *Archiv EuroMedica*, 2017. – T. 7. – № 1. – C. 8-13.
20. **STEINER C.C.** The use of cephalometrics as an aid planning and assessing orthodontic treatment // *American J. Orthodontics*, 1960. – № 46. – P. 721.
21. **DOMENYUK D.A., VEDESHINA E.G., DMITRIENKO S.V.** Correlation of dental arch major linear parameters and odontometric indices given physiological occlusion of permanent teeth in various face types // *Archiv EuroMedica*, 2016. – Vol. 6. – № 2. – P. 18-22.
22. **DOMENYUK D.A., VEDESHINA E.G., DMITRIENKO S.V.** Efficiency evaluation for integrated approach to choice of orthodontic and prosthetic treatments in patients with reduced gnathic region // *Archiv EuroMedica*. – 2015. – Vol. 5. – № 2. – P. 6-12.
23. **PORFYRIADIS M.P., DOMENYUK D.A., DAVYDOV B.N., VEDESHINA E.G., DMITRIENKO S.V.** Features

- of tactics and principles orthodontic treatment of patients with dental arches asymmetry caused by different amounts of antimeres (Part III). The Dental Institute. 2018; 79(2): 89-92. (In Russ.).
24. **DOMENYUK D.A., SHKARIN V.V., PORFYRIADIS M.P., DMITRIENKO D.S., DMITRIENKO S.V.** Algorithm for forecasting the shape and size of dental arches front part in case of their deformations and anomalies // *Archiv EuroMedica*, 2017. – T. 7. – № 2. – C. 105-110.
 25. **DMITRIENKO S.V., KRAYUSHKIN A.I., DMITRIENKO D.S., EFIMOVA E.YU.** Topographic-anatomical features of the structure of the bone tissue of the mandibular segments // *Dentistry*. – 2007. – T. 86. – № 6. – P. 10-12.
 26. **DOMENYUK D.A., TASHUEVA L.V., ZELENSKY V.A., IVANCHEVA E.N.** Evaluation of microvasculature tissues viability after the imposition of removable orthodontic appliances in children and adolescents // *Archiv EuroMedica*, 2013. – Vol. 3. – № 1. – P. 5-9.
 27. **ZELENSKY, V.A.** Integral indicator for orthodontic carequality control / V.A. Zelensky, D.A. Domenyuk, M.V. Baturin, I.V. Zelensky, A.V. Kokareva, A.V. Zenina // *Medical news of North Caucasus*. 2014. – Vol. 9. – № 1. – P. 80-83. (In Russ., English abstract). DOI: 10.14300/mnnc.2014.09022.
 28. **DOMENYUK D.A., VEDESHINA E.G., DMITRIENKO S.V.** Mistakes in Pont (Linder-Harth) method used for diagnosing abnormal dental arches in transversal plane // *Archiv EuroMedica*, 2016. – Vol. 6. – № 2. – P. 23-26.
 29. **DOMENYUK, D.A.** Modern classification of dental arches / D.A. Domenyuk, S.V. Dmitrienko // *Archiv EuroMedica*, 2014. – Vol. 4. – № 2. – P. 14-16.
 30. **PORFYRIADIS M.P., DOMENYUK D.A., DAVYDOV B.N., DMITRIENKO S.V., BUDAYCHIEV G.M.-A.** Variability of cephalometric indices in men and women with mesocefalic form of the head and various constitutional types of face (Part III). The Dental Institute. 2018; 80(3): 84-87. (In Russ.).
 31. **DMITRIENKO S.V., LEPILIN A.V., FOMIN I.V., DOMENYUK D.A., DAVYDOV B.N.** Study of morphology, methods of comparison of tooth and alveolar arcs by results of anthropometry and cellular-beam computer tomography (Part II). The Dental Institute. 2018; 80(3): 70-74. (In Russ.).
 32. **DOMENYUK D.A., VEDESHINA E.G., DMITRIENKO S.V.** Teeth sizes in their correlation with parameters of dentofacial arches and maxillofacial area based on native cranial preparations examination. *Kubanskij nauchnyj medicinskij vestnik*. 2016;(2):71-79. (In Russ.) DOI:10.25207/1608-6228-2016-2-71-79.
 33. **DOMENYUK D.A., VEDESHINA E.G., DMITRIENKO S.V.** The use of craniometric and morphological studies in the assessment of structural elements of the temporomandibular joint. *Kubanskij nauchnyj medicinskij vestnik*. 2017;1(1):33-40. (In Russ.) DOI:10.25207/1608-6228-2017-1-33-40.
 34. **DOMENYUK D.A., PORFYRIADIS M.P., BUDAYCHIEV G. M-A.** Contemporary methodological approaches to diagnosing bone tissue disturbances in children with type i diabetes. *Archiv EuroMedica*, 2018; 8(2): 71-81.
 35. **ARNETT G.W. JALIC J.S., KIM J.** Soft tissue cephalometric analysis: diagnosis and treatment planning of dentofacial deformity // *American J. Of Orthodontics and Dentofacial Orthopedic*. 1999. № 116. P. 239-253
 36. **DOMENYUK, D.A.** Study of the spectrum of dental composites biological activity in model experiments in vitro / D.A. Domenyuk, E.G. Vedeshina, V.A. Zelensky, K.G. Karakov, M.P. Porfiriadis, I.A. Bazikov, F.N. Gilmiyarova // *Medical news of North Caucasus*. 2016. – Vol. 11. – № 2. – P. 179-183. (In Russ.) DOI: 10.14300/mnnc.2016.11031.
 37. **DOMENYUK, D.A.** Semiquantitative evaluation of caries microflora in patients with dental and alveolar abnormalities and different severity of morphofunctional disturbances / D.A. Domenyuk, E.G. Vedeshina, V.A. Zelensky, K.G. Karakov, M.P. Porfiriadis // *Medical news of North Caucasus*. 2015. – Vol. 10. – № 3. – P. 238-241. (In Russ.) DOI: 10.14300/mnnc.2015.10055.
 38. **IVCHENKO L.G., BYKOV I.M., BASOV A.A., GILMIYAROVA F.N., DOMENYUK D.A., BUDAYCHIEV G. M-A., IVANUTA S.O.** Development and justification of the estimation algorithm of the bone system metabolism in children with type 1 diabetes mellitus. *Kubanskij nauchnyj medicinskij vestnik*. 2018; 25(5): 35-47. (In Russ., English abstract). DOI: 10.25207/1608-6228-2018-25-5-35-47.
 39. **DOMENYUK D.A., ILIJEV D.M., BUDAYCHIEV G.M.-A., VEDESHINA E.G., DMITRIENKO S.V.** Optimization of diagnostics and planning of orthodontic treatment of patients with dentofacial anomalies based on the results of morphometric studies of the anterior dental arch. *Kubanskij nauchnyj medicinskij vestnik*. 2017; 25(5): 14-21. (In Russ., English abstract). DOI: 10.25207 / 1608-6228-2017-24-5-14-21.
 40. **KOROBKEEV A.A., DOMENYUK D.A., SHKARIN V.V., DMITRIENKO S.V., WEISHEIM L.D., KONNOV V.V.** Anatomical features of the interdependence of the basic parameters of the dental arches of the upper and lower jaws of man. *Medical news of North Caucasus*. 2018. – Vol. 13. – № 1-1. – P. 66-69. (In Russ., English abstract). DOI – <https://doi.org/10.14300/mnnc.2018.13019>
 41. **SHKARIN V.V., PORFIRIADIS M.P., DOMENYUK D.A., DMITRIENKO D.S., DMITRIENKO S.V.** Setting reference points for key teeth location in case of abnormal dental arch shape // *Archiv EuroMedica*. – 2017. – V.7. – № 2. – C. 111-117.
 42. **DOMENYUK D.A., DMITRIENKO S.V., VEDESHINA E.G., RISOVANNY S.I., PORFYRIADIS M.P., BUDAYCHIEV G.M.-A.** Methods of biometrical diagnostics in transversal direction in patients with mesognathic type of dental arches. *Kubanskij nauchnyj medicinskij vestnik*. 2017; 24(6): 26-34. (In Russ., English abstract). DOI: 10.25207 / 1608-6228-2017-24-6-26-34.

43. **DMITRIENKO S.V., DAVYDOV B.N., V.V. SHKARIN, DOMENYUK D.A.** Algorithm for determining the size of artificial teeth by the morphometric parameters of the face in people with full adentia. *Dentistry*. 2018; 97(6): 57-60.
44. **DAVYDOV B.N., DOMENYUK D.A., BYKOV I.M., IVCHENKO L.G., DMITRIENKO S.V.** Modern possibilities of clinical, laboratory, X-ray studies in preclinical diagnosis and prediction of the risk of developing periodontal diseases in children with diabetes mellitus type one. Part I. *Periodontology*. 2018; Vol. XXIV; 3-24 (88): 4-11. (In Russ.). DOI: 10.25636/PMP1.2018.3.1.
45. **DOMENYUK D.A., DMITRIENKO S.V., VEDESHINA E.G., PORFYRIADIS M.P., BUDAYCHIEV G.M-A.** Analytical approach in evaluating the relations of odontometric indicators and linear parameters of dental arcs in people with various face types. *Kubanskij nauchnyj medicinskij vestnik*. 2018; 25(1): 73-81. (In Russ., English abstract). DOI: 10.25207 / 1608-6228-2018-25-1-73-81.
46. **DOMENYUK D.A., PORFYRIADIS M.P., ILIJEV D.M., BUDAYCHIEV G.M-A., VEDESHINA E.G., DMITRIENKO S.V.** Dimensional and topographic features of the elements of the temporomandibular joint with mesial occlusion complicated by dentition defects. *Kubanskij nauchnyj medicinskij vestnik*. 2017;24(4):54-64. (In Russ., English abstract). DOI: 10.25207 / 1608-6228-2017-24-4-54-64.
47. **KARSLIEVA A.G., DOMENYUK D.A., ZELENSKY V.A.** Mixed saliva trace element composition in children with dentoalveolar anomalies through apparatus-involved treatment // *Archiv EuroMedica*, 2014. – Vol. 4. – № 1. – P. 29-35.
48. **DOMENYUK D.A., ZELENSKY V.A., RZHEPAKOVSKY I.V., ANFINOGENOVA O.I., PUSHKIN S.V.** Application of laboratory and x-ray general studies un early diagnostics of metabolic disturbances of bone tissue in children with autoimmune diabetes mellitus. *Entomology and Applied Science Letters*. 2018; 5(4): 1-12.
49. **DAVYDOV B.N., DOMENYUK D.A., DMITRIENKO S.V.** Changes of the morphological state of tissue of the paradontal complex in the dynamics of orthodontic transfer of teeth (experimental study). *Periodontology*. 2018; Vol. XXIII; 1 (86): 69-78. (In Russ.).
50. **DOMENYUK D.A., ZELENSKY V.A., DMITRIENKO S.V., ANFINOGENOVA O.I., PUSHKIN S.V.** Peculiarities of phosphorine calcium exchange in the pathogenesis of dental caries in children with diabetes of the first type. *Entomology and Applied Science Letters*. 2018; 5(4): 49-64.
51. **DOMENYUK D.A., DAVYDOV B.N., DMITRIENKO S.V., LEPILIN A.V., FOMIN I.V.** Diagnostic opportunities of cone-box computer tomography in conducting craniomorphological and craniometric research in assessment of individual anatomical variability (Part I). *The Dental Institute*. 2018; 81(4): 52-55. (In Russ.).
52. **SHKARIN V.V., DOMENYUK D.A., PORFYRIADIS M.P., DMITRIENKO D.S., DMITRIENKO S.V.** Mathematical and graphics simulation for individual shape of maxillary dental arch // *Archiv EuroMedica*, 2017. – T. 7. – № 1. – C. 60-65.