

<https://doi.org/10.35630/2199-885X/2019/9/3.15>

SURVIVAL AFTER SURGICAL TREATMENT OF SYNCHRONOUS METASTATIC LESION OF THE ADRENAL TUMORS

Avetik Muradyan^{1,2✉} , **Andrey Kostin**^{2,3} ,
Aleksandr Tolkachev¹, **Nikolay Vorobyev**^{1,4}

¹ P.A. Hertsen Moscow Oncology Research Center, Moscow

² Peoples' Friendship University of Russia, Moscow

³ National Medical Research Radiological Center, Obninsk

⁴ First Moscow State Medical University, Moscow, Russia

✉ mdmuradyan@gmail.com

ABSTRACT — This article presents an assessment of the survival rate of 68 patients after surgical treatment of synchronous metastatic lesion of the adrenal tumors in the Department of oncurology of the P.A. Hertsen Moscow Oncology Research Center — branch of FSBI NMRRC of the Ministry of Health of Russia, Moscow, Russian Federation. Almost all patients (86.8%) underwent open access adrenalectomy, the rest — laparoscopic access. The duration of follow-up for all patients was on average 14.0 months. The morphological type of tumor affects the survival of patients with synchronous metastatic adrenal lesions. We recorded significantly greater survival in patients with renal cell carcinoma compared to non-small cell lung cancer, melanoma and urothelial cancer ($p=0.001$).

FINDINGS: in patients with synchronous adrenal metastatic lesions after surgical treatment, the one — year survival rate is $53.5\pm 6.5\%$, three-year survival rate is $29.8\pm 6.8\%$, and five-year survival rate is $14.9\pm 1.1\%$

KEYWORDS — Metastatic adrenal tumors, surgical treatment, laparoscopic adrenalectomy, open adrenalectomy, survival.

INTRODUCTION

Currently, adrenal tumors are detected with greater frequency due to the better quality of radiation diagnosis [1, 2]. Adrenal tumors, including metastatic tumors, are detected in about 3.4% of cases with computed tomography [3].

Because of the rich vascularization, the adrenal glands are the organ of metastasis lesions [4]. The adrenal glands (NP) hold the fourth place in the frequency of localization of metastatic tumors [5]. In the presence of cancer history, the probability of having metastatic lesions is about 50% [6]. Currently, the main method of treatment of synchronous metastatic lesions of the adrenal is surgical: open, laparoscopic, robot-assisted adrenalectomy. Therefore, the survival of patients with synchronous metastatic of the adrenal

tumors lesions after surgical treatment is of particular interest to doctors.

Aim

Assessment of survival after surgical treatment of synchronous metastatic lesion of the adrenal tumors.

METHODS

The study included 68 patients who were treated in the P.A. Hertsen Moscow Oncology Research Center — branch of FSBI NMRRC of the Ministry of Health of Russia in the period from 1991 to 2019. All patients have agreed to the processing of personal data. All patients had synchronous adrenal metastatic lesion and underwent simultaneous surgery in the form of removal of the primary tumor and adrenalectomy. For all patients, we evaluated overall survival-time from adrenalectomy to the date of last contact or death of the patient, and progression-free survival — calculated from the date of adrenalectomy to disease progression. We did not include patients with metachronous metastatic adrenal lesions in the study.

Statistical processing of the results obtained during the study was carried out using the program SPSS Statistics 23 (IBM, USA). Survival in groups of patients in a certain period of time was carried out using the Kaplan-Meyer method.

RESULTS

All patients were around 52–64 years old. The number of men prevailed over the number of women: 51(75%) and 17(25%). The most common localization of the primary tumor was renal cell carcinoma (RCC) - 58(85.3%). There were 5(7.4%) people with non-small cell lung cancer (NSCLC). The diameter of the adrenal tumor was on average 44 mm (4.0–170.0 mm). The grouping of patients based on the side of the adrenal lesion is shown in fig. 1.

The majority of patients underwent open access adrenalectomy — 59 (86.8%), the remaining 7(10.3%) — laparoscopic access. There were 2 (2.9%) conversions. A small number of patients to whom adrenalectomy was performed by laparoscopic access is related to the presence of infiltrative tumor growth, tumor thrombus of the renal or inferior Vena cava, the presence of previous surgical interventions on the abdominal organs, the tumor size (more than 5 cm).

The median follow-up time was 14.0 months. In patients with synchronous adrenal metastatic lesions, one-year, 3-year, and 5-year survival rates were— $53,5 \pm 6,5\%$, $29,8 \pm 6,8\%$ and $14,9 \pm 1,1\%$. Median progression-free survival in patients with synchronous adrenal metastatic lesions was 9 months (1-140).

One-year, three- and five-year progression-free survival in patients with synchronous adrenal metastatic lesions was $40,3 \pm 6,2\%$, $19,2 \pm 5,6\%$, $8,5 \pm 4,9\%$ accordingly.

There was no statistically significant difference in survival of patients with primary tumor localization in lung and metastatic adrenal lesions in the studied group of patients ($p=0.911$; Log Rank).

In Cox regression analysis, survival in patients with synchronous adrenal lesions was influenced by the morphological type of tumor (with a favorable prognosis for PCR compared to NSCLC, melanoma and urothelial cancer), $p=0.001$.

DISCUSSION

Analysis of literature data shows that adrenal metastases occur in 40–50% of patients with liver cancer or PCR, in 25% of patients with melanoma or NSCLC, breast cancer — 35% [7]. In our study, most of the metastases came from the kidney (PCR) — 85.3%. According to Frilling A. et al., 89% of patients with adrenal metastatic lesions had a history of PCR [8].

According to Lin C. T. et al. the size of the adrenal tumor has a prognostic value [4]. Thus, 25% of adrenal lesions less than 3 cm were metastatic, but 86% of adrenal metastatic lesions were greater than 6 cm [4].

The size of the adrenal tumor also plays a role in the planning of surgical treatment tactics. Thus, laparoscopic adrenalectomy is effective in patients with tumor size up to 5 cm [9]. With a larger tumor size (≥ 5 cm), there may be an increased risk of postoperative complications and a decrease in the efficacy of treatment after laparoscopic adrenalectomy [9].

The stage of malignancy of the primary tumor also has a prognostic value in the prognosis of metastatic lesions of the adrenal tumors [4]. Thus, only 25% of patients (6 out of 24) in the clinical stage of T1 or T2 had metastatic adrenal malignancies. And, in the clinical stage of T3 or T4, up to 56% of patients (14 out of 25) had metastatic adrenal lesions [4].

The overall survival prognosis for patients with metastatic adrenal cancer leaves much to be desired. After adrenalectomy, about 25% of patients with isolated adrenal metastasis achieve 5-year relapse-free survival [10]. In another study, the overall 5-year survival rate was 33% (calculated using the Kaplan-

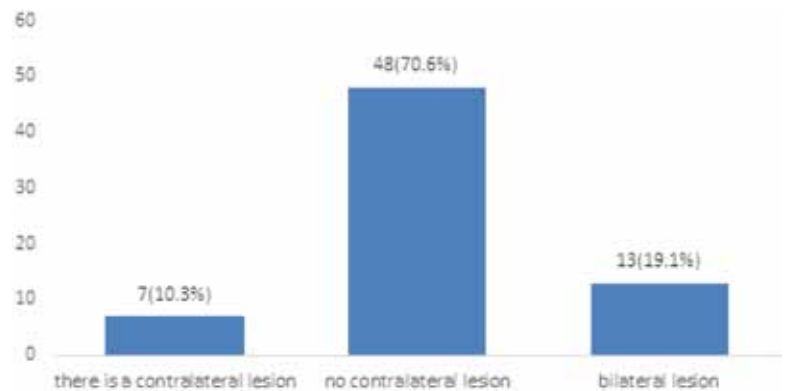


Fig. 1. Number of patients based on the side of the adrenal tumors lesion

Meier method) [11]. The Russian study showed a total five-year survival rate of $46,8 \pm 11,7\%$ in patients with secondary adrenal tumors after adrenalectomy (calculated by the Kaplan-Meier method) [12]. Our study showed a lower overall five-year survival rate in the studied patients — 14.9% (Kaplan-Meier calculation), perhaps due to the morphological type of tumors and their differentiation (with a tendency to low- and undifferentiated).

CONCLUSIONS

The most common primary tumor localization was the renal cell carcinoma (85.3%). In the prognosis of survival in synchronous metastatic lesions of the adrenal tumors, it is necessary to take into account the morphological type of tumor. In patients with synchronous metastatic adrenal tumors lesions after surgical treatment, one-year survival occurs in every second case, three-year survival occurs in every third case, five-year survival happens in every seventh case.

REFERENCES

- BOLAND GW, BLAKE MA, HAHN PF, MAYO-SMITH WW.** Incidental adrenal lesions: principles, techniques, and algorithms for imaging characterization. *Radiology* 2008;249(3):756–775. doi: 710.1148/radiol.2493070976.
- KOSTIN A.A., TOLKACHYOV A.O., KUL'CHENKO N.G., MURADYAN A.G.** Morphological analysis of the results of surgical treatment of patients with adrenal tumors. *Morphology*. 2017; 151(3): 78–78a.
- NIEMAN LK.** Approach to the patient with an adrenal incidentaloma. *J Clin Endocrinol Metab*. 2010; 95(9): 4106–4113. doi: 4110.1210/jc.2010-0457
- LIN CT, SHAO IH, CHUANG CK, PANG ST, CHANG YH.** Isolated Synchronous Adrenal Lesions in Patients with Newly Diagnosed Extra-Adrenal Malignancies. *International surgery*. 2018; 103(3–4): 207–213. DOI: 10.9738/INTSURG-D-18-00019.1

5. **BARTLETT E.K., SIMMONS K.D., WACHTEL H., ROSES R. E., FRAKER D.L., KELZ R. R., KARAKOUSIS G.C.** The rise in metastasectomy across cancer types over the past decade. *Cancer*. 2015; 121(5): 747–757. doi:10.1002/cncr.29134
6. **FASSNACHT M., ARLT W., BANCOS I., DRALLE H., NEWELL-PRICE J., SAHDEV A., DEKKERS O. M.** Management of adrenal incidentalomas: European Society of Endocrinology Clinical Practice Guideline in collaboration with the European Network for the Study of Adrenal Tumors. *European Journal of Endocrinology*. 2016; 175(2): G1–G34. doi:10.1530/EJE-16-0467
7. **MANSMANN G, LAU J, BALK E, ROTHBERG M, MIYACHI Y, BORNSTEIN SR.** The clinically inapparent adrenal mass: update in diagnosis and management. *Endocr Rev* 2004; 25(2):309–340.
8. **FRILLING A, TECKLENBORG K, WEBER F, KUHL H, MULLER S, STAMATIS G.** Importance of adrenal incidentaloma in patients with a history of malignancy. *Surgery* 2004; 136(6):1289–1296.
9. **GRYN A, PEYRONNET B, MANUNTA A, BEAUVAL JB, BOUNASR E, NOUHAUD FX, RIOUX-LECLERCQ N, CARON P, THOULOZAN M, VERHOEST G.** Patient selection for laparoscopic excision of adrenal metastases: A multicenter cohort study. *International journal of surgery*. 2015; 24: 75–80. DOI: 10.1016/j.ijssu.2015.10.038
10. **DUH QY.** Resecting isolated adrenal metastasis: why and how? *Ann Surg Oncol*. 2003; 10(10):1138–1139.
11. **SEBAG F, CALZOLARI F, HARDING J.** Isolated adrenal metastasis: the role of laparoscopic surgery. *World J. Surg.*2006; 30(5): 888–892.
12. **KOLOSOKOV V.V.** Metastatic adrenal tumors: Retrospective data review of a 10-year observation. *Annals of surgery*. 2007; 6: 35–37.