

# MRI IN THE DIAGNOSIS OF ASCARIASIS OF THE SMALL INTESTINE IN ADULTS

Y.Y. Peresta<sup>1</sup>, V.I. Ahij<sup>1</sup>, M.V. Ihnat<sup>1</sup>, O.A. Borishevsjka<sup>2</sup>,  
V.I. Ihnat<sup>2</sup>, I.I. Lemko<sup>2</sup>

<sup>1</sup> Medical center «Diamed» Ltd., Uzhhorod, Ukraine

## INTRODUCTION

In the world about 1.5 billion people suffer of ascariasis and its symptoms. Ascariasis is the result of a harmful invasion of the *Ascaris lumbricoides* — a worm from a group of nematodes. Basically, ascarids parasitize in the small intestine, but with the ability to migrate from their usual habitat, in turn, can lead to the defeat of other organs — the lungs, the heart and the brain. Single- and multi-component infections cause human illness, which causes complications from mild to severe and even fatal cases [2]. From the side of the digestive system, there are described such life-threatening complications as intestinal obstruction, acute cholangitis, biliary obstruction, liver abscesses, appetite, acute pancreatitis, perforation of the intestine, mesenteric ischemia, granulomatous peritonitis and even bowel gangrene. As a rule, ascariasis often affects children, but not the exception is and infection of adults. Clinical manifestations are due to toxic reactions, immunological responses and manifestations of obstruction due to the presence of adult nematodes in the gastrointestinal tract. [3–5]. Most of these neglected tropical diseases are found in areas with poor sanitation and hygiene; However, an increase in the number of trips and migrations made infections, also more common in non-endemic areas.

For your consideration we would like to present the following clinical case:

## CASE PRESENTATION

The patient G., 17.11.1967 enrolled on 12.04.18 in the medical center "Diamed" with complaints of periodic constipation, pain in the left iliac region, general weakness, loss of appetite, bloating, considers himself ill for about 6 months when the complaints first appeared. For 6 months he did not apply for medical assistance. From the anamnesis it is known: hepatitis, tuberculosis and sexually transmitted diseases are not relevant. Allergostable.

In 2000 the operation was performed: resection of the stomach by Bilroth–II due to ulceration of the stomach.

**OBJECTIVELY:** the general condition of a patient of moderate severity. Skin and visible mucous of the usual color. Peripheral lymph nodes are not palpable. Breathing vesicular over the entire surface of the pulmonary fields. Ps 18 per min. Heart activity is rhythmic. AT 140/80 mm. ht Art.. The abdomen is soft, sensitive in the left iliac region, takes part in the act of breathing. Physiological exits are periodic constipation. S-m of Pasternatsky is negative on both sides. The liver and spleen are not enlarged.

**LOCAL:** palpation of the stomach is soft, sensitive in the left iliac region. Percussion — box sound in the right half of the abdomen. The tumor is not palpated. Peripheral lymph nodes are not palpable.

12.04.18 — Hepatitis B (Quick test on HBsAg — negative

12.04.18 — Hepatitis C (Quick test on a / t to HCV) — negative

12.04.18 — HIV test 1 and 2 types (qualitatively) — negative

12.04.18 — Quick Test for Syphilis (CITO-TEST Syphilis) — Negative

12.04.18 — Review X-ray of chest organs # 2481 — right, extended non-structural root in the projection of the I–II intercostal shadow with fuzzy contours.

12.04.18 — X-ray examination of abdomen # 2481 — under the right dome of the diaphragm, the inflated loops of the intestine. Free gas, bowls of Kloybera — not detected.

12.04.18 — Ultrasound examination of abdomen: Splenomegaly.

12.04.18 — MRI of abdomen: Considering the anamnestic data (postoperative surgical intervention for stomach ulcers) and obtained visualization data, it is necessary to conduct a differential diagnosis between: secondary (acquired adhesive disease) dolichosigma; nonplastic lesion of the large intestine. Enteritis. Splenomegaly. Chronic pancreatitis. But it is not possible to exclude ascariasis of the small intestine (see Fig. 1).

12.04.18 — Consultation of the therapist: CHD. Cardiosclerosis is atherosclerotic. Syndrome of dysfunction of the sinus node (sinus bradycardia) CH and Art. Splenomegaly. Chronic pancreatitis.

12.04.18 — Echocardiography: slight expansion of the ascending department of the aorta. Hypertrophy of LS. Dilatation of LP. Degenerative changes in

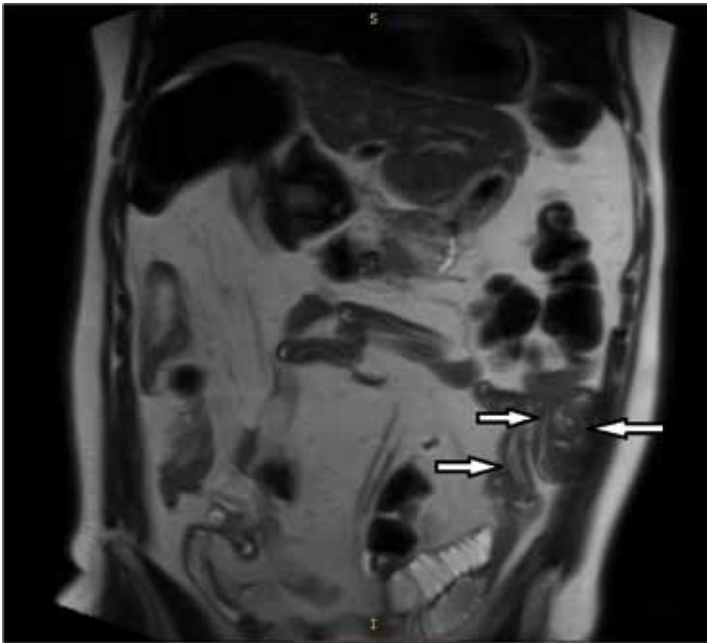


Fig. 1.

the aorta, AK, MK. Insignificant insufficiency of MK. Mobile MPP without signs of bypass. LH (at the time of inspection) does not have. Pericardium is free. SZM — saved.

13.04.18 — VFEGDS: Condition after resection of the stomach in the B–II. In the small intestine, an ascaster tangle is visualized.

13.04.18 — VFCS: Partial review due to the presence of large amounts of feces. The large intestine is inspected to the transverse colon. Subsequent review was not conducted due to inadequate training. In the sigmoid mucosa of the mucous membrane with ulcers. Take a biopsy.

13.04.18 — Consultation of the gastroenterologist: Ascariidosis with intestinal defeat. Partial intestinal obstruction. Condition after resection of the stomach by Bilroth–II. Chronic pancreatitis, phase n / remission. Splenomegaly

## CONCLUSION

Thus, taking into account the data of additional studies in the patient G., 1967. Diagnosis of ascariasis of the small intestine (further gastroduodenitis), however, despite a small number of [6–7] reports in research and scientific literature devoted to MRI abdominal studies, our specialists suspect this pathology, the pathognomonic symptom of the "lace" is hypertensive in T2SE mode, T2fsSE sequences are linear forms of inclusion in the lumen of the small intestine, which are visualized mainly in the left half of the abdomen (see Fig. 2).

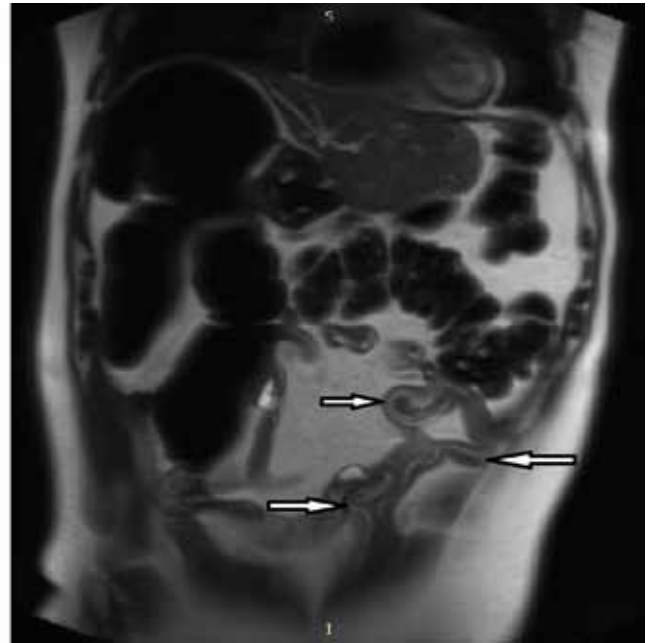

Fig. 2.

This supplementary method may be useful in patients with suspected ascariasis, especially in adulthood.

## REFERENCES

1. PULLAN RL, SMITH JL, JASRASARIA R, BROOKER SJ. Global numbers of infection and disease burden of soil transmitted helminth infections in 2010. *Parasites Vectors*. 2014;7:37. doi: 10.1186/1756-3305-7-37. [PMC free article] [PubMed] [Cross Ref]
2. TAYLOR-ROBINSON DC, MAAYAN N, SOARES-WEISER K, DONEGAN S, GARNER P. Deworming drugs for soil-transmitted intestinal worms in children: effects on nutritional indicators, haemoglobin, and school performance. *Cochrane Database of Syst Rev*. 2015;7 [PMC free article] [PubMed]
3. DAS AK. Hepatic and biliary ascariasis // *J. Global Infect Dis*. — 2014. — 6. — 65-72. doi: 10.4103/0974-777X.132042.
4. *Ascaris lumbricoides* in the nasogastric tube after operation on a patient with the diagnosis of acute mesenteric ischemia: case report / A.C. Cicek, D. Cundogdu, S. Direkel, C. Oztuc // *Turkiye Parazitol. Derg.* — 2013. — № 37 (3). — P. 212-215.
5. Intrahepatic Duct Stones Harboring Ascariasis Ova: A Case Report / C.F. Lee, W.C. Lee, R.C. Wu, T.C. Chen // *Medicine (Baltimore)*. — 2016. — № 95 (12): e3139. doi: 10.1097/MD.0000000000003139
6. DING ZX, YUAN JH, CHONG V ET-AL. 3 T MR cholangiopancreatography appearances of biliary fscariasis. *Clin Radiol*. 2011; 66 (3): 275-7. Doi: 10.1016/j.crad.2010.11.004 – Pubmed citation
7. SINHA R, RAJESH A, RAWAT S ET-AL. Infections and infections. *Clin Radiol*. 2012;67 (5): 495-504. Doi:10.1016/j.crad.2011.10.022 – Pubmed citation