

THE IMPORTANCE OF PRENATAL DIAGNOSIS OF CONGENITAL HEART DISEASES FOR PLANNING OF DELIVERY AND POSTNATAL CARE



Elena D. Bespalova, MD
Professor, Director



Olga A. Pitirimova, MD
Obstetrician, Vice-Director



Maria N. Bartagova
Physician



Rena M. Gasanova
Cardiologist, Junior Researcher

Bakoulev Center for Cardiovascular Surgery, Moscow

INTRODUCTION

Congenital heart disease is the most common disorder of newborns, affecting one out of every 100 babies. CHD is 6 times more common than chromosomal abnormalities and 4 times more common than neural tube defects. About 25% of all infant deaths resulting are due to congenital malformations and one third of these deaths are of infants with cardiac abnormalities.

Most forms of CHD can be detected in utero, especially the severe ones with considerable fetal and postnatal morbidity and mortality. The prenatal diagnosis of major CHD requires further assessment for extracardiac (about 65%) and chromosomal (about 43%) abnormalities [1].

Fetal cardiology includes the assessment of the fetal heart for CHD and arrhythmias, the management of affected fetuses, including parental counseling for the therapeutic options, the planning of the delivery and the postnatal care.

This requires a close collaboration between obstetricians, neonatologists and pediatric cardiologists and cardiovascular surgeons.

Although there has been a great improvement in the diagnosis of CHD both prenatally and postnatally due to the availability of echocardiography. The goals of fetal echocardiography are to exclude CHD and, when present, to diagnose the specific malformations of the heart.

Echocardiography will determine whether the fetus has the type of structural abnormality and details

Abstract

Objective

Prenatal echocardiography is very important for diagnosis CHD, the management of affected fetuses, including parental counseling for the therapeutic options, the planning of the delivery and the postnatal care.

Methods

Multiple B-scan planes, Doppler color flow mapping and pulsed Doppler, 3-4 Dimensional Fetal Echocardiography. Methods of the echocardiographic identification of fetal CHD are: postnatal echocardiography, angiography, surgery, or autopsy.

Results

A total of 8619 fetal echocardiograms were obtained during the period between 2000–2010 years from which 3672 fetuses with a prenatal diagnosis of CHD were enrolled.

Conclusion

Prenatal diagnosis of major CHD was associated with improved preoperative clinical status of these infants and must include detailed extracardiac and intracardiac assessment to predict the risks of surgical treatment. Prenatal diagnosis of CHD may guide the timing and optimal location of delivery. The deliveries of patients with major cardiac anomalies in a tertiary obstetrics center close to a pediatric cardiac facility or cardiovascular surgery center allows optimal perinatal and postnatal management.

Keywords

Prenatal diagnosis, fetal echocardiography, congenital heart diseases, delivery, postnatal care.

specific CHD. This information is very important for choice of surgical repair after birth [2].

METHODS

Definition of fetal CHD was attempted from multiple scan planes including four-chamber, long- and short-axis as well as aortic arch and ductal arch views. We use 3-4 Dimensional Fetal Echocardiograms for diagnosis complex CHD after 2 dimensional echo. Optimal 3-Dimensional Fetal Echocardiograms were obtained between 22 and 27 weeks of gestation [Fig. 1, 2].

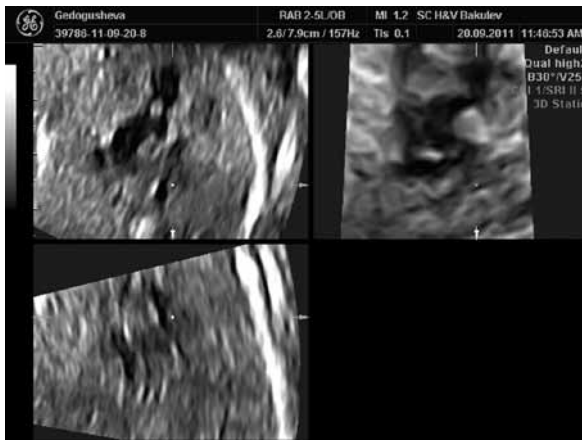


Figure 1. 3D-multiplanar reconstruction mode (FAST). Plane A: the tree-vessels view modification. Truncus arteriosus, aorta, pulmonary artery. 23 weeks gestation

The stages of Fetal Echo: The early transvaginal fetal echocardiogram at 12 to 14 weeks of pregnancy (for exclude major heart malformations for groups of risk). But early transvaginal fetal diagnosis will be repeat over 2 weeks.

The optimal transabdominal fetal echocardiogram – at 16 to 22 weeks of pregnancy. By this time, details of the fetal cardiac anatomy can be well visualized, such as the atrioventricular and ventriculoarterial connections.

Fetal echocardiographic images may be difficult after 32nd–34th weeks of gestation because of

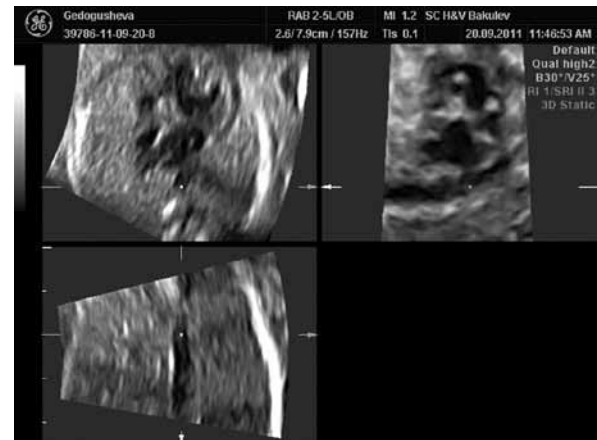


Figure 2. 3D-multiplanar reconstruction mode (FAST). Plane A: the five chamber view modification. Ventriculoseptal defect (RV – right ventricle). 23 weeks gestation

3-D echocardiography enables more detailed evaluation of dynamic fetal cardiac function, but there are also technical problems with 3-D fetal echocardiograms [5,6].

Doppler color flow mapping and pulsed Doppler interrogation were used to facilitate identification of great vessel relationship, location and severity of ventricular outflow obstruction[3].

Initial fetal echocardiograms were obtained between 12 and 39 weeks of gestation (median 24.5 weeks). Major cardiac malformations should be followed serially by fetal echocardiography as progressive alterations in flow may affect growth of cardiac structures over time: for example, Very often, after prenatal diagnosis of hypoplastic left-heart syndrome (HLHS) couples have been offered termination of pregnancy

But “Termination of pregnancy should not be proposed when it is only a small left ventricle (on echo), because many of those patients end up with only coarctation of the aorta.” A second echo should be carried out in these cases.

Methods of the echocardiographic identification of fetal CHD are: postnatal echocardiography, angiography, surgery, or autopsy.

fetal rib shadowing, fetal position, or maternal body habitus.

RESULTS

A total of 8619 fetal echocardiograms were obtained during an period between 2000–2010 years from which 3672 fetuses with a prenatal diagnosis of CHD were enrolled. Here is the sample of data for three years. The number of cases is enough for statistic analyze.

CHD usually are diagnosed during the first echo.

The number of echocardiographic studies was ranging from one to four examinations. Maternal age was from 17 to 41 years old.

The stages of Fetal Echo:

- 23% of fetal echocardiograms were obtained before 18 weeks of gestation.
- 48% of fetal echocardiograms were obtained between 19–24 weeks of gestation.
- 29% of fetal echocardiograms were obtained between 25–39 weeks of gestation.

Next CHD have been diagnosed prenatally (Table 1). The most CHD are severe CHD. Outcome of prenatal diagnosis of CHD (Table 2).

Table 1. Names of CHD

Name of cardiac anomalies	N (abs.)	(%)
Atrioventricular canal (partial + complete)	15+148	6,8
Hypoplastic left heart syndrome	161	6,7
Hypoplastic right heart/tricuspid atresia	49	2,1
Conotruncal anomalies	409	17,1
Pulmonary atresia with VSD+intact ventricular septum	43+17	1,8+0,7
Isolated Ventricular septal defects	914	38,2
Coarctation of the aorta, interruption of aortic arch	57	2,4
Anomalous pulmonary venous connection	12	0,5
Congenital AV + semilunar valvar anomaly	29+34	1,2+1,4
Single ventricle	65	2,7
Potential ASD	61	2,5
Cardiac tumors	25	1,1
Congenital coronary artery anomalies, fistulae	5	0,2
Other complex cardiac anomalies	348	14,6
All	2392	100

Table 2. Outcome

Outcome	N (abs.)	(%)
The termination of pregnancy	698	29,2
Intrauterine fetal death	4	0,2
Neonatal death soon after birth	39	1,6
Fetal evolution (Small VSD)	619	25,9
Surgical repair before 1 year	604	25,2
Surgical repair after 1 year	223	9,3
Are followed up by doctors, SR is planned for the future	205	8,6
All	2392	100

The main reasons of termination of pregnancy (29,2%) are early diagnosis, a one-ventricle outcome, or multiple malformations.

Intrauterine fetal death took place about 0,2%.

The main reasons of neonatal death (1,6%) are severe CHD and multiple malformations.

Fetal evolution (25,9%). We are speaking about small muscular ventricular septal defects. Most of small ventricular septal defects are muscular VSD. This disease are the most frequent abnormalities diagnosed in utero. VSD account for 30% of all cardiac defects. Small muscular defects of the ventricular septum are subject to a high spontaneous closure rate in utero, often after 26–28 weeks of gestation, and in the first years of life.

In most liveborn infants, complete surgical repair can be achieved.

Surgical repair before 1 year were made in 25,9%. There were ductus-dependent CHD, radical correc-

tion of AVC, TF, two-forked cava-pulmonary anastomosis. Surgical repair after 1 year were made in 9,3%. There were most radical correction of Ventricular septal defects, ASD.

Are followed up by doctors, surgical repair is planned for the future in 8,6%. There were Congenital valvar anomalies, small septal defects.

MISTAKES OF PRENATAL DIAGNOSIS OF CHD

The number of mistakes of diagnosis – 81 from 2392 cases (3,4%).

The most difficult diagnosis of Truncus arteriosus and Pulmonary atresia with ventricular septal defect. It can be difficult to determine the morphology of the central pulmonary arteries and to locate the source of pulmonary blood supply [Fig.3]. It is difficult initial diagnosis of Coarctation of aorta after 34th–36th week of gestation [Fig.4].

In contrast, the prenatal diagnosis of TOF or DORV with subaortic VSD agreed in most cases with the postnatal findings.

DISCUSSION

In general, prenatal diagnosis most major CHD make results of the delivery, the postnatal care and surgical repair much better.

Fetal echocardiography has opportunity to study the most important parameters of fetal heart with major CHD for postnatal surgical repair.

Important parameters of fetal echocardiography in last weeks (32–36 weeks of gestation) are:

- Left/right ventricular diastolic dimensions in M-mode, B-mode (right-to-left ventricular disproportion: cardiomegaly, dilatation of right ventricle, right atrium or left chambers of heart; hypoplastic right or left heart);
- Atrioventricular and semilunar valves's dimensions (valve's stenosis/atresia or dilatation);
- Study of ejection fraction (Fetal heart contractility including its ability to fill and to eject blood to the body and back to the placenta);
- Inefficient of fetal circulatory (pericardial effusion, AV regurgitation, fetal non-immune hydrops, fetal arrhythmias;
- Ultrasound diagnosis of anatomical details of specific CHD.

Ultrasound details for specific CHD by the planning of the delivery and the postnatal care

Most important Ultrasound details for major CHD are:

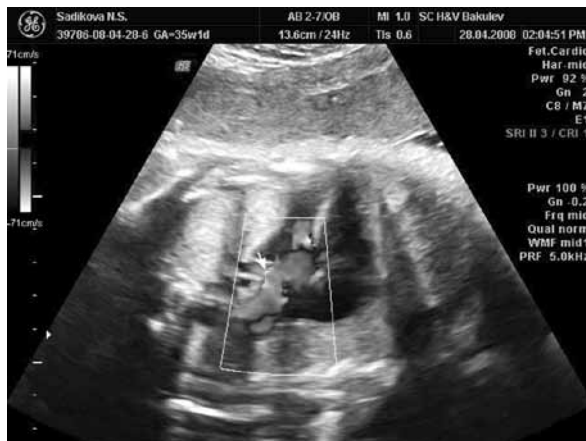

Figure 3. 2-dimensional color Doppler image at 27 weeks gestation. The five chamber view modification. Truncus arteriosus – TA. Pulmonary artery – arrow. Aorta – Ao. Left ventricle – LV. Right ventricle – RV

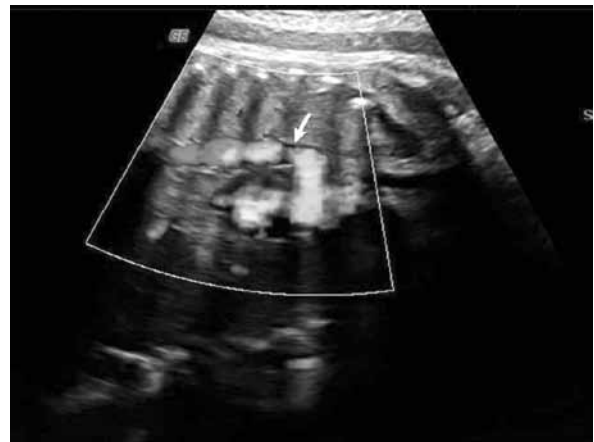

Figure 4. 2-dimensional Power Doppler at 30 weeks gestation. Aortic Arch view. Coarctation of aorta – arrow

For Conotruncal anomalies:

- fetal echocardiographic definition of the great artery relationship;
- left ventricular diastolic dimension;
- dimension of foramen ovale (restrictive foramen ovale – early closure of a flap valve in the fetal heart and restriction of flow across the foramen ovale);
- dimension of ductus arteriosus [4], type of coronary arteries;
- the location of associated ventricular septal defect;
- the presence/absence of ventricular outflow tract obstruction with the other diagnostic modalities.

For Pulmonary atresia:

- the presence/absence of ventricular septal defect;
- intracardiac anatomy; presence and size of the branch pulmonary arteries;
- source of pulmonary blood supply; side of the aortic arch.

Hypoplastic left/ right heart:

- mitral/ tricuspid valvar anomaly (congenital parachute mitral valve, stenosis/ atresia);
- aortic valve or aortic root disease, stenosis/atresia PA, Right ventricular outflow obstruction, dimension of foramen ovale and ductus arteriosus DA.

Review of fetal evolution of CHD

Some CHD can be observed in utero. It is so interesting to prenatal diagnosis of mild Coarctation of aorta and mild valvar stenosis.

Fetal development is not affected, because of the unique fetal circulation. The large ductus arteriosus allows equalization of systolic blood pressure in the great

arteries, thus a pressure gradient does not develop in utero. But we may see dilated right ventricle resulting from increased systemic vascular resistance.

What is a program of prenatal Cardiology in our clinic?

Our program of prenatal cardiology includes:

A team of expert cardiologists trained in the evaluation and diagnosis of fetal heart problems.

What to Expect from Fetal Cardiology?

That plan will usually include:

- An accurate diagnosis;
- Prompt communication of test results to the referring health care provider;
- Tests, such as amniocentesis or magnetic resonance imaging (MRI), to look for other congenital problems;
- Directing of the Pregnancy;
- Follow-up assessments, communication and counseling (when needed);
- Close monitoring of the unborn baby's health and development;
- Careful planning of a mom's delivery that includes staying in close contact with obstetrician and cardiology doctors;
- Method of choice of delivery is natural delivery;
- Complete care of the unborn baby following delivery, with access to the cardiovascular surgery center and cardiothoracic surgery teams;
- Consultations with other services at our clinic, which may include cardiothoracic surgery, genetics and psychology services;
- Thorough and caring counseling to help couples understand the options for diagnosis, treatment and surgery;

- After delivery, the baby will be cared for at the Heart Institute. Should the newborn require surgery, our cardiothoracic surgeons can perform even the most complex surgery for congenital heart diseases.

CONCLUSION

1. Fetal cardiology is very important for diagnosis CHD, the management of affected fetuses, including parental counseling for the therapeutic options, the planning of the delivery and the postnatal care.
2. Prenatal diagnosis of major CHD was associated with improved preoperative clinical status of these infants and must include detailed extracardiac and intracardiac assessment to predict the risks of surgical treatment.
3. Prenatal diagnosis of CHD may guide the timing and optimal location of delivery. The deliveries of patients with major cardiac anomalies in a tertiary obstetrics center close to a pediatric cardiac facility or cardiovascular surgery center allows optimal perinatal and postnatal management.

REFERENCES

1. **ALLAN L.D.** Fetal congenital heart disease: diagnosis and management. // *Curr. Opin. Obstet. Gynecol.* – 1994. – v.6. – p. 45–49.
2. **MAREK JAN.** Prenatal ultrasound screening of congenital heart disease in an unselected national population: a 21-year experience. / Jan Marek, Viktor Tomek, Jan Scovranek, Viera Povysilova, Milan Samanek. // *Heart.* 2011, 97,124–130.
3. **TIINA H.OJALA.** Fetal heart failure. / Tiina H. Ojala, Lisa K. Hornbergeri. // *Frontiers in Bioscience S2,* 891–906, June 1, 2010.
4. **WEICHERT J.** The fetal ductus arteriosus and its abnormalities – a review. / Weichert. J, Hartge D.R., Axt-Fliender R. // *Congenital Heart Disease.* 2010 Sept.–Oct.5(5): 398–408.
5. **YAGEL S.** Added value of tree-/four-dimensional ultrasound in offline analysis and diagnosis of congenital heart disease. / S.Yagel, S.M.Cohen, D.Rosenak, B. Messing, M. Lipschuetz, O.Shen and D.V.Valsky // *Ultrasound Obstet Gynecol,* 2011, 37: 432–437.
6. **YEO L.** Four-chamber view and «swing technique» (FAST) echo: a novel and simple algorithm to visualize standart fetal echocardiographic planes. / L.Yeo, R. Romero, C. Jodicke, G. Ogge, W. Lee, J.P.Kusanovic, E. Vaisbuch and S.Hassan. // *Ultrasound Obstet Gynecol,* 2011, 37: 423–431.