

<http://dx.doi.org/10.35630/2199-885X/2021/11/2/G.1>

BIOCHEMICAL STUDY OF MENSTRUAL BLOOD AND A MATHEMATICAL MODEL FOR DIAGNOSIS OF UTERINE MYOMAS

Received 03 March 2021;
Received in revised form 14 April 2021;
Accepted 19 April 2021

Yuliana Ukhanova , Adelya Zoeva ,
Olga Tishkova , Svetlana Belyavskaya ,
Adilya Ayupova , Pavel Loginov 

Astrakhan State Medical University, Astrakhan, Russia

✉ loginovpv77@mail.ru

ABSTRACT — Uterine myomas or fibroids (UF) are the most common tumors in women, which can cause serious complications, often require surgical interference and cause infertility. The authors proposed a comprehensive approach to solving this issue, which includes identifying the characteristic structures of the solid phase of menstrual discharge and the introduction of a mathematical model for predicting the growth rates of UF. Patients were divided into three groups of women of reproductive age. The control group included 41 relatively healthy patients. The second group consisted of 40 women with simple UF (group 1), and 30 women with proliferating UF were included in the third group (group 2). Development and implementation of a method for diagnosing UF, which includes the study of morphological structures of solid phase of menstrual blood and levels of ligands inducing apoptosis and proliferation, allows to find the most optimal solution for this clinical task. A mathematical model is proposed for predicting the growth rates of UF. The safety and atraumatic method of morphological analysis of menstrual fluids makes it possible to apply it effectively in the work of an outpatient clinic.

KEYWORDS — uterine fibroids, proliferating uterine fibroids, proliferation, apoptosis, menstrual blood.

INTRODUCTION

Uterine myomas or fibroids (UF) are the most common benign tumors of female genital organs in the world [1, 2, 3, 4], affecting at least 20–40% of women during their lifetime. Moreover, it is UF that accounts for one third to half of all hysterectomies. According to the results of a study carried out by a group of scientists headed by I.S. Sidorova in 2000, it was proposed to distinguish two clinical and morphological types of the disease: simple and proliferating UF [3]. Moreover, at the same time, other researchers studied this aspect and came to the similar conclusions [1]. Simple and proliferating UF can vary on a number of features, such as, the location of nodes, their number, size, ultrasound characteristics.

At the cellular level, simple UF is characterized by low activity of proliferation and angiogenesis processes in combination with increased synthetic activity and severity of the stromal component [4]. At the same time, proliferating UF is characterized by rapid growth and high mitotic activity [5]. Biological fluids, such as menstrual blood, cervical mucus and endometrial lavage, contain markers that allow one to suspect and identify the presence of abnormalities in the organs of the reproductive system [1, 6, 7, 8, 10].

The development and implementation of a method for the diagnosis of UF, including the study of the morphological structures of the solid phase of menstrual blood and the levels of ligands inducing apoptosis (LIA) and proliferation (LIP), makes it possible to find the most optimal solution to this clinical problem [9, 11].

The aim of the study

was to develop a diagnostic method for proliferating uterine fibroids by determining the structural features of menstrual blood, identifying LIA and LIP in them, and to make a mathematical model for predicting the possible growth rate of UF.

MATERIAL AND METHODS

Women of reproductive age (23–45 years old) were divided into three groups. The investigation was held at the Gynecology and Obstetrics Department of Astrakhan State Medical University. The control group included 41 relatively healthy women. The second group consisted of 40 women with simple UF (group 1), and the third group consisted of 30 women with proliferating UF (group 2). The investigation was held in accordance with the universal ethical standards.

The distribution of women into groups with simple and proliferating UF, as well as the exclusion of women with «false» rapid growth was carried out on the basis of the results of histological examination of myoma nodes, ultrasound data, acute phase proteins, clinical picture and growth rates of myoma. The study included only patients with a «true» type of rapid UF growth. In the course of the work, data on the number, localization, and size of myoma nodes were analyzed, obtained by ultrasound performed on days 5–7 of the menstrual cycle.

Menstrual blood was taken in the most abundant days of menstruation. The obtained samples were centrifuged at 3000 rpm for 5 min. The resulting supernatants were used for further morphological and immunochemical studies. The supernatant was dropped onto a glass slide and covered with a coverslip. The material obtained was dried at room conditions for 2–3 days [12].

The analysis of the structures of the solid phase of menstrual fluid formed during the edge dehydration was carried out using microscope Leica MZ 12.5 (Switzerland) equipped with a Leica ICC 50 digital camera.

The content of LIP and LIA in the menstrual blood supernatant was determined by enzyme immunoassay using Bender MedSystems kits (Austria) [11].

The study results were processed using Microsoft Office 2010, Statistica software (StatSoft Inc., USA version 8.0). To study and compare the data obtained, the Kruskal-Wallis, Kolmogorov-Smirnov tests, as well as the method of correlation analysis were used. Description of qualitative features was reproduced in percent (%), absolute values (n/N) and contingency tables with the definition of χ^2 ; description of quantitative data was realized in the form of $M \pm m$ [11]. The results were considered reliable at $p < 0.5$.

RESULTS

In group 1, the nodes were located mainly in the fundus and body of the uterus, which was recorded in 26 patients and accounted for 65.0% of observations ($p < 0.05$). In group 2, the nodes were located intraligamentally (in 40.0% of patients), in the area of fundus and body of the uterus (in 43.3% of women), as well as in the isthmus (in 16.7% of patients). The number of myoma nodes with simple UF varied from 1 to 4 and averaged 1.6 ± 0.14 , while with proliferating UF there was a significant increase in the number of nodes to 5–7, with average number of 4.0 ± 0.14 ($p < 0.05$). The size of the dominant node with simple UF was 2.6 ± 0.19 cm, with proliferating UF 5.7 ± 0.48 cm ($p < 0.05$).

It has been proved that the presence of parallel structures in the morphological picture of the biological fluid indicates the presence of hyperplastic processes in patients [12, 13]. In this regard, a significant increase in their percentage in group 2 confirmed the predominance of proliferation processes in this contingent [11]. At the microscope level, proliferation markers — parallel (Fig. 1) and fibrous (Fig. 2) structures are seen in patients with endometrial hyperplastic processes.

The conducted immunochemical study showed that in menstrual blood of the control group, the

level of LIP was 3.0–4.8 ng/ml, in group 1 it risen to 4.8–6.4 ng/ml, and in group 2 up to 11.1–14.7 ng/ml. In turn, LIA in the control group was in the range of 35.1–36.8 pg/ml, in group 1 it decreased to 24.0–27.0 pg/ml, and in group 2 up to 20.0–22.5 pg/ml [11, 14, 15].

Correlation analysis in the group of patients with simple UF (group 1) revealed a relationship between lattice structures and levels of LIP ($r = +0.3$) and LIA ($r = +0.28$), transitional forms and concentration of LIP ($r = +0.27$) and dendritic forms and LIA ($r = +0.3$) [11]. In patients with proliferating MM (group 2), there was a direct relationship between the LIP level and the size of uterus ($r = +0.35$) according to the ultrasound examination of pelvic organs [15]. The results of the investigation are summarized in Table 1.

At the final stage, to derive a mathematical formula, the binary logistic regression method was used:

$$P = \frac{1}{1 + e^{-z}},$$

where: P is the probability of the event occurring; e — constant value (2.72), which serves as the base of natural logarithm; z — the degree of inverse logarithm is calculated by the formula:

$$z = 2.172 FS + 2.238 PS + 1.568 NN - 10.915$$

where: FS — fibrous structures, PS — parallel structures, NN — the number of nodes [16].

In the case when P was more than 0.5, the risk of developing proliferating UF increased (more than 50%). In this group of patients, at the next stage, the levels of LIA and LIP were analyzed. With an increase in LIP of more than 11.1 ng/ml and a decrease in LIA of less than 22.5 pg/ml, the risk of an event tends to approach 100% [11].

The introduction of this model into clinical practice will enable, with a high degree of probability, to make a prognosis of the proliferative potential of myoma nodes for each individual patient, which, in turn, gives an answer to the question of the advisability of using hormone therapy in the pre- and postoperative period in women who need myomectomy.

Patients with a high risk of developing proliferating UF, for whom myomectomy is indicated, need either isolated or combined pre- and postoperative treatment with the drug class of gonadotropin-releasing hormone agonists in order to suppress proliferative processes. At the same time, for patients with simple UF, a one-stage treatment, including myomectomy, is sufficient, followed by a decision on planning pregnancy.




Fig. 1. Parallel structures in an analytical cell. Magnification 100×

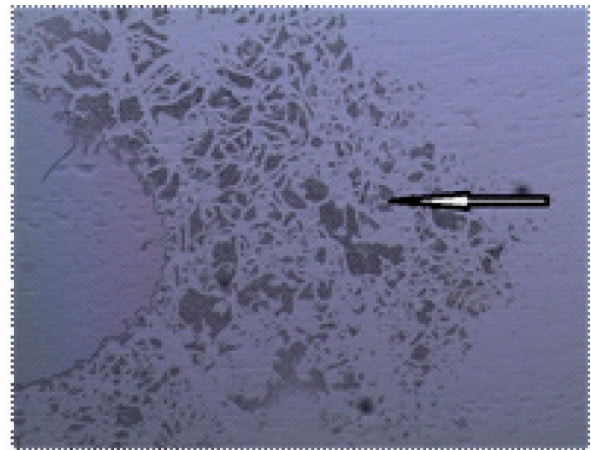


Fig. 2. Fibrous structures in an analytical cell. Magnification 100×

Table 1. Structural elements of the solid phase of the menstrual blood

Isotropic forms	Control group (n = 41), %	Group 1 (n = 40), %	Group 2 (n = 30), %
Dendritic	41,5	47,5	13,31
Transitional	34,2	45,0	3,31
Lamellar	9,8	27,52	3,31
Parallel	2,4	37,52	83,31
Fibrous	0	10,0	50,01

Note: 1) $p < 0.05$ — significant differences compared to group 1; 2) $p < 0.05$ — significant differences compared with the control group

CONCLUSION

Therefore, identification of characteristic structural features of menstrual blood in patients with different clinical and morphological variants of the tumor, along with the determination of levels of LIP and LIA, allows not only to make an individual prognosis, to plan the management and treatment of patients, but also ultimately helps achieve the main goal — the implementation of reproductive life planning (RLP). At the same time safety and simplicity of morphological method of biological fluids makes it possible to apply actively this method in an outpatient care facility.

REFERENCES

1. CIAVATTINI A., CLEMENTE N., DELLI C.G., DI G.J., GIANNUBILO S.R., TRANQUILLI A.L. (2015). Number and size of uterine fibroids and obstetric outcomes. *The Journal of Maternal-Fetal & Neonatal Medicine*, 28(4): 484–488. DOI: 10.3109/14767058.2014.921675
2. DIKAREVA L.V., SHVAREV E.G., BIRYUKOVA A.F. (2012). Biochemical features of the endometrial secretion of patients with uterine fibroids. *Astrakhanskiy meditsinskiy zhurnal*, 7(2), 175–178. (in Russ.)
3. SIDOROVA I.S., HUNANYAN A.L., KOGAN E.A., GURIEV T.D. (2010). Uterine fibroids in young patients: clinical and pathogenetic features. *Akusherstvo, ginekologiya, reprodukcija*, 4(1), 16–20.
4. BUYANOVA S.N., YUDINA N.V., GUKASYAN S.A., MGELIASHVILI M.V. (2012). Modern aspects of the growth of uterine fibroids. *Rossiiskii vestnik akusheraginekologa*, 4, 42–48. (in Russ.)
5. DIKAREVA L.V., SHVAREV E.G., AYUPOVA A. K. (2008). Clinical and diagnostic aspects of fast-growing uterine fibroids. *Problemy reprodukcii*, 14(6):20–25.
6. DIKAREVA L.V., SHVAREV E.G., OVODENKO D.L., SHRAMKOVA I.A., ARUTYUNYAN A.A. (2008). Method for diagnosing endometrial pathology in patients with uterine fibroids. Patent RF, no. 2334987.
7. BUYANOVA S.N., LOGUTOVA L.S., BABUNASHVILI E.L., GORBUNOVA T.N. (2003). Reproductive prognosis in uterine fibroids. *Rossiiskii vestnik akusheraginekologa*, 4: 47–49. (in Russ.)
8. DIKAREVA L.V., SHVAREV E.G., AYUPOVA A.K. (2008). Clinical and prognostic significance of the rapidly growing uterine fibroids. *Uspehi sovremennogo estestvoznaniya*, 8: 102–105. (in Russ.)

9. **DIKAREVA L.V., AJUPOVA A.K., SHVAREV E.G., UKHANOVA JU.YU., ZOEVA A.R., GADZHIEVA P.H.** Diagnostic aspects of obstetric and gynecological pathology of solid phase morphology of biological liquids (review). *Estestvennye nauki*, 3: 40–48. (in Russ.)
10. **DIKAREVA L.V., SHVAREV E.G., SHRAMKOVA I.A., SHVAREV G.E.** (2008). A method for diagnosing a rapid-growing uterine myoma. Patent RF, no. 2332167.
11. **UKHANOVA JU.YU.** Markers of proliferation and apoptosis in the diagnosis of proliferating uterine fibroids. (2017). *Aktualnyye voprosy sovremennoy meditsiny*, 192–194. (in Russ.)
12. **SHABALIN V.N., SHATOHINA S.N.** (2001). The morphology of the human biological fluids (303–303). *Horizostom Publ.* (in Russ.)
13. **SHATOHINA S.N., SHABALIN V.N.** (2004). Method of diagnosing a cell hyperplasia organism. Patent RF, no. 2234856.
14. **STEWART E.A., COOKSON C.L., GANDOLFO R.A., SCHULZE-RATH R.** (2017). Epidemiology of uterine fibroids: a systematic review. *BJOG: An International Journal of Obstetrics & Gynaecology*, 124(10):1501–1512. DOI: 10.1111/1471-0528.14640
15. **UKHANOVA JU.YU., DIKAREVA L.V., SHVAREV E.G., AJUPOVA A.K.** (2015). An integrated approach to the diagnosis of uterine fibroids and assessment of its growth rate. *Tumors of female reproductive system*, 11(4):71–75. (in Russ.)
16. **UKHANOVA JU.YU., DIKAREVA L.V., SHVAREV E.G., AJUPOVA A.K.** (2015). An innovative approach to the diagnosis of fast-growing uterine fibroids. *Astrakhanskiy meditsinskiy zhurnal*, 10(3):106–114. (in Russ.)