

SPECIFIC FEATURES OF TRANSVERSAL AND VERTICAL PARAMETERS IN LOWER MOLARS CROWNS AT VARIOUS DENTAL TYPES OF ARCHES

Article history:
Submitted 19 April 2019
Accepted 5 July 2019

Vladimir Shkarin¹, Vasily Grinin², Ruslan Halfin³,
Sergey Dmitrienko⁴, Dmitry Domenyuk^{5*}

¹ Department of public health and postgraduate education, Volgograd state medical university, Volgograd, Russia

² Department of Public Health and Health Care, First Sechenov Moscow State Medical University, Moscow, Russia

³ Graduate School of Health Management, First Sechenov Moscow State Medical University, Moscow, Russia

⁴ Department of Dentistry, Pyatigorsk Medical-Pharmaceutical Institute (Branch of Volgograd State Medical University, Pyatigorsk, Stavropol Region, Russia)

⁵ Department of General Dentistry and Child Dentistry, Stavropol State Medical University, Stavropol, Russia

*Corresponding Author: domenyukda@mail.ru

ABSTRACT — The article offers a view on the outcomes of morphometric studies focusing on vertical, transverse parameters of the lower large molars in patients with various dental types of arches. The subject of the study was the lower molars segments obtained from jaws cast models of 65 people with physiological occlusion, a full set of permanent teeth and various types of dental system (Group 1 — normodontia; Group 2 — macrodontia; Group 3 — microdontia). For transversal direction morphometry, the vestibular-lingual size of the tooth crown and neck were used, as well as the intertubercular distance. To measure the vertical parameters, the height of the vestibular, lingual odontomere and that of the tubercle were identified. The results of the study show that people with physiological occlusion and permanent teeth macrodontia, the vertical, transversal parameters exceed those featured by people with normodontia and microdontia types of the dental system. The obtained odontometric features can be used through diagnosing occlusal relationships and identifying various pathological, physiological abrasions of varying degrees of occlusal surface loss.

KEYWORDS — jaws cast model biometry, lower jaw molars, physiological occlusion, tooth morphological structure.

INTRODUCTION

The specific feature about the large molars group is the multitubercle shape of the occlusal surface. The complexity of the odontomers structure and their variability have been presented from the point of gender and race dimorphism, as well as in view of age-related changes in the masticatory apparatus [1–6]. Odon-

ometry issues have key positions in clinical dentistry, morphology, odontology, and forensic medicine. At the same time, people with different types of face and dental arches reveal variability of morphometric odontological parameters [7–13]. Modern classifications of face types and dental arches in people with physiological occlusion have been presented [14–19]. Teeth measurements in orthodontic clinics are the basic positions when it comes to diagnosing pathology of occlusal relationships and selecting treatment methods [20–26].

Methods of dental arches biometric study are diverse and imply not identifying linear dimensions alone, yet also allow reproducing the shape of dental arches via mathematical simulation [27–29].

Methods for maxillofacial X-ray examination have been presented, which allow identifying the key teeth position, molars in particular, to further choose the treatment method [30–39]. It has been noted that the size of the teeth is largely determined by the head facial part parameters, in particular, the diagonal dimensions that correlate with the size of the teeth and the dental arches in both jaws [40, 41].

The morphometric features of the teeth and dental arches in people with various types maxillofacial anomalies and deformations have been shown, as well as differential diagnostics algorithms have been presented [42–46].

Odontometric studies serve the basis for the choice of methods to treat patients with occlusion issues and dental arches defects of various length and localization, including full edentulism, and offer criteria for determining the effectiveness of treatment [47–50]. However, the presented works, as a rule, have odontometry measuring the mesial-distal size of the teeth crowns. It is very rarely that studies focus on measuring the transversal and vertical size of teeth, and even if so, they are carried out on the dental-maxillary segments isolated from native preparations [51].

Physiological abrasion, which is a loss of occlusal surface within the enamel, is of adaptive nature and is a factor preventing teeth functional overload. Physiological abrasion, as a slow-progressing compensated process, improves the chewing function and establishes

conditions for the lower jaw free movement, as well as for the smooth sliding of the tooth rows through various articulation stages. Pathological abrasion, as a rapidly-progressing process of the teeth enamel and dentine abrasion, causes changes in the dental and nearby tissues, and is characterized by functional disorders of the temporomandibular joint and masticatory muscles. Reducing height of the tooth crown with pathological abrasion affects the size of the face gnathic part, which requires prosthetic measures and use of structural materials [52–55].

Identifying the boundaries between the physiological and pathological teeth abrasion is an urgent task for clinical dentistry. Given that, relevant are the issues of studying the chewing surface tubercles in case of physiological norm, which determined the aim of this study.

Aim of study:

to evaluate the height of crowns and tubercles of the lower large molars with permanent teeth physiological occlusion.

MATERIALS AND METHODS

For this study, 65 people (29 men, 36 women) aged 21–35 years old were examined with physiological occlusion and integral dentition. After receiving the prints, diagnostic models from super-gypsum class III “Elite Model” (“Zhermack”, Italy) were cast. Measurements of the parameters of the teeth and dental arches were carried out on the obtained diagnostic models. A digital caliper “NORGAU ABS” was used as a toolkit (division value 0.01mm). Odontometric studies were carried out according to the method of A.A. Zubov (1968), and included the definition of mesio-distal and vestibular-lingual size of the crown. The longitudinal length of the dentition was calculated by the Nance method, as the sum of the mesial-distal diameters of the teeth forming it. The third molars were not taken into account in the measurements, since they are as variable as possible (Fig. 1).

Measurement was carried out on the lower molars segments obtained from 65 pairs of jaws cast models. The models were divided into three groups — with normodontia, macrodontia and microdontia.

Given the data from previous studies, dental arches were referred to normodontia where the length (or the sum of the mesial-distal crown size of 14 teeth) ranged from 112 to 118 mm (24 pairs of cast models). Sizes below or above the specified range were attributed to micro- (22 pairs of cast models), or to macrodontia (19 pairs of cast models) (Fig. 2).

In view of the specific five-tubercle shape of the first lower molars, a cut of the distal segment was per-

formed between the spots located at the apexes of the distal vestibular and distal lingual tubercles. The distal tubercle height (hypoconulide) was not taken into account within our study, since its size varied over a wide range, up to the complete reduction of the tubercle.

On the tooth segment picked out from the cast model, spots were made with the reference lines drawn. The main points for the study were the teeth necks and the tubercle apexes on the chewing surface (Fig. 3).

The major reference was the line connecting the neck of the vestibular and the lingual contours of the crown, marked as the neck line (1). From the middle of the cervical line and perpendicular to it, a conditional median tooth vertical was drawn (2). Perpendicular to the conventional median vertical, a line was drawn through the point located at the junction of the chewing surface tubercles, which was marked as the occlusion plane (3).

The conditional tubercle lines (4 and 5) pointed at the location of the tubercles relative to the conventional median vertical and occlusal planes of the tooth.

In the transversal direction, the vestibular-lingual (VL) crown and cervical sizes were measured, as well as the intertubercular distance.

To measure the vertical parameters, the above-mentioned reference lines were used. The height of the vestibular (a) and lingual (c) odontomers was measured from the cervical line to the reference points on the articular tubercles tops. The height of the tubercles (b and d) was measured to the occlusal plane level. The data obtained through the study were subjected to statistical processing using the methods of parametric and non-parametric analysis following the outcomes of testing the compared sets for their normal distribution. The statistical analysis was performed using IBM SPSS Statistics 23 software.

RESULTS AND DISCUSSION

An analysis of the height parameters of the lower chewing teeth crowns and the transversal dimensions between the vestibular and the lingual contours helped reveal the morphometric features of the molars in various types of dental systems.

Measuring the mesial segment of the first lower molar, isolated from jaws cast models obtained from Group 1 patients (normodontic dental system), revealed that the crown width in its widest part was 10.83 ± 0.07 mm. In the cervical region, the buccal-lingual size was 10.35 ± 0.05 mm, while between the tubercles tops it was 7.39 ± 0.03 mm. In the distal segment, the crown and neck dimensions were 10.56 ± 0.08 mm and 10.25 ± 0.06 mm, whereas the intertubercular distance was 7.25 ± 0.04 mm (Table 1).

Vertically, the height of the crown mesial part on




Fig. 1. Photos of plaster models of the upper (a) and lower (b) jaws with contours for measuring the longitudinal length of the dental arch

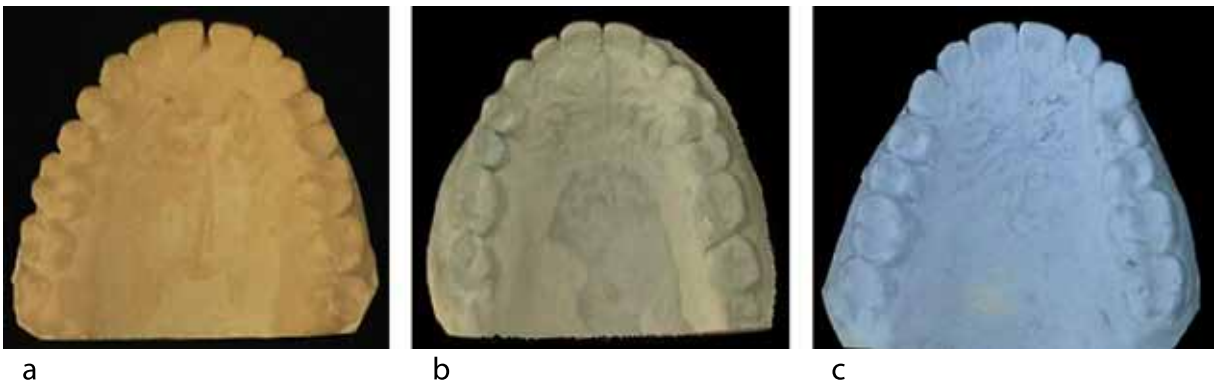

Fig. 2. Photos of plaster models of the upper jaw of patients with normodontia (a), microdontia (b), macrodontia (c).

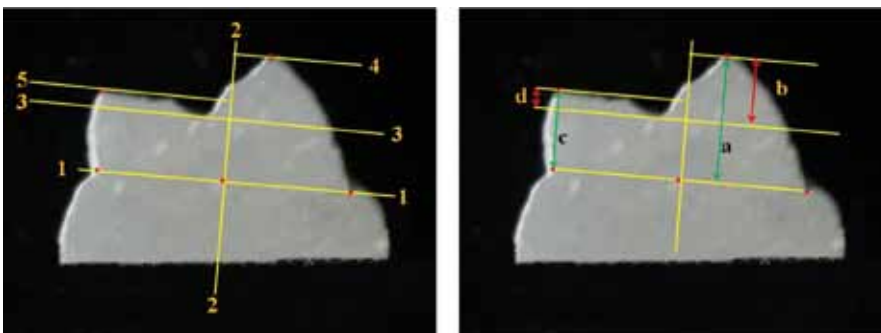


Fig. 3. Images of the right lower molar mesial segment with marked reference lines and points for measurement (see text)

the vestibular side was significantly above ($p \leq 0.05$) that on the lingual side of the tooth, which affected the height of the chewing surface tubercles. The height of the mesial vestibular tubercle was 2.20 ± 0.01 mm, and that of the mesial lingual tubercle was 1.32 ± 0.01 mm.

The second molar represented two sectors as well, the anterior (mesial) and the posterior (distal) ones. The crown width of the anterior segment was

10.32 ± 0.06 mm, distal — 9.85 ± 0.07 mm. Therefore, the second molar was slightly smaller in size than the first one, which confirms the ideas expressed by most respective experts.

The vertical parameters of the second lower molar in the crown anterior sector were 5.35 ± 0.04 mm from the vestibular side and 4.23 ± 0.02 mm from the lingual side. The height of the anterior vestibular tubercle was

Table 1. Lower molars crowns in people with physiological occlusion and normodontia of permanent teeth, (mm), ($M \pm m$)

The parameters studied	The size of the segment isolated from the lower jaw:			
	at the first molar in the segment:		the second molar in the segment:	
	mesial	distal	mesial	distal
Vestibular lingual size of the tooth crown	10,83±0,07	10,56±0,08	10,32±0,06	9,85±0,07
Vestibular lingual size of the tooth neck	10,35±0,05	10,25±0,06	9,87±0,04	9,71±0,06
Inter-hill distance	7,39±0,03	7,25±0,04	6,10±0,05	5,22±0,04
Height of buccal odontomer	5,87±0,02	4,86±0,03	5,35±0,04	4,62±0,02
Height of buccal tubercle	2,20±0,01	1,73±0,02	1,25±0,02	0,97±0,01
Height of lingual odontomer	5,21±0,02	5,26±0,03	4,23±0,02	3,67±0,03
The height of the lingual tubercle	1,32±0,01	1,32±0,02	1,51±0,03	1,36±0,01

1.25±0.02 mm, and the mesial lingual tubercle height — 1.51±0.03 mm.

In Group 2, the patients had larger teeth than with normodontia, which was quite obvious. The length of the dental arch in the group as a whole was 118.54±1.39 mm, which was typical of the macrodontic dental system.

The width of the first molar crown between the vestibular and lingual contours equators was 10.90±0.05 mm. In the cervical area, the buccal-lingual size was 10.68±0.06 mm, while between the tubercles peaks it measured 8.12±0.04 mm. Therefore, the tooth sizes in the transversal direction were significantly above those in Group 1.

Table 2 offers a view on the major vertical dimensions in Group 2.

type of dental system. Besides, there was an increase observed in the height of the tubercles chewing surface as compared with Group 1.

In the second permanent lower molar, at the anterior segment, the crown height and that of the tubercle from the vestibular side was 5.33±0.06 mm and 2.29±0.02 mm, and from the lingual side, the crown height was 5.03±0.06 mm, while the tubercle height was 1.65±0.04 mm. In the distal sector, the height of the vestibular contour of the crown and of the tubercle was 5.49±0.07 mm and 2.30±0.04 mm, respectively. On the lingual side, the height of the crown and tubercle was 4.48±0.05 mm and 1.81±0.03 mm, respectively.

In Group 3, the teeth were significantly smaller than in the other groups. The length of the dental arch in the group as a whole was 98.73±1.39 mm, which

Table 2. Lower molars crowns in people with physiological occlusion and macrodontia of permanent teeth, (mm), ($M \pm m$)

The parameters studied	The size of the segment isolated from the lower jaw:			
	at the first molar in the segment:		the second molar in the segment:	
	mesial	distal	mesial	distal
Vestibular lingual size of the tooth crown	10,90±0,05	10,70±0,08	10,67±0,06	10,16±0,07
Vestibular lingual size of the tooth neck	10,68±0,06	10,25±0,07	10,46±0,05	9,97±0,09
Inter-hill distance	8,12±0,04	7,75±0,03	7,06±0,06	6,58±0,08
Height of buccal odontomer	6,03±0,05	6,01±0,07	5,33±0,06	5,49±0,07
Height of buccal tubercle	2,39±0,01	2,41±0,03	2,29±0,02	2,30±0,04
Height of lingual odontomer	5,83±0,05	5,47±0,07	5,03±0,06	4,48±0,05
The height of the lingual tubercle	1,78±0,02	1,83±0,02	1,65±0,04	1,81±0,03

The mesial height of the first large molar crown from the vestibular side was 6.03±0.05 mm, from the lingual side — 5.83±0.05 mm. The obtained data on the vertical dimensions of the crown indicated that during macrodontia, the vertical parameters were slightly above that in people with the normodontic

was typical of the microdontic type of the lower dental system.

The size of the first molar crown between the equator points of opposite contours was 10.59±0.06 mm. In the cervical area, the vestibular-lingual area measured 9.45±0.04 mm, while between

the tubercles tops it was 5.28 ± 0.02 mm. Therefore, the teeth sizes in the transversal direction were significantly smaller ($p \leq 0.05$) compared to Group 1 (Table 3).

behind the development of pathological abrasion in hard dental tissues, and the choice of optimal treatment tactics with a minimum likelihood of complications development.

Table 3. Lower molars crowns in people with physiological occlusion and microdontia of permanent teeth, (mm), ($M \pm m$)

The parameters studied	The size of the segment isolated from the lower jaw:			
	at the first molar in the segment:		the second molar in the segment:	
	mesial	distal	mesial	distal
Vestibular lingual size of the tooth crown	10,59±0,06	10,37±0,08	10,09±0,05	9,64±0,09
Vestibular lingual size of the tooth neck	9,45±0,04	10,12±0,03	9,41±0,08	9,22±0,06
Inter-hill distance	5,28±0,02	6,32±0,05	5,38±0,03	4,88±0,07
Height of buccal odontomer	4,62±0,08	3,95±0,04	3,71±0,07	3,52±0,04
Height of buccal tubercle	1,81±0,02	1,56±0,06	1,05±0,04	1,34±0,06
Height of lingual odontomer	4,20±0,07	3,45±0,03	3,78±0,08	3,97±0,05
The height of the lingual tubercle	1,62±0,03	1,56±0,04	1,57±0,02	1,46±0,03

On the cast model mesial sectors of the first lower molars, the crown height from the vestibular and lingual sides were smaller than that in Group 1, and measured 4.62 ± 0.08 mm and 4.20 ± 0.07 mm, respectively, which had its effect on the height of the vestibular and lingual tubercles.

In the second molar, the following measurements were obtained: the height of the vestibular contour of the mesial and distal sectors was 3.71 ± 0.07 mm and 3.52 ± 0.04 mm, and at the lingual contour — 3.78 ± 0.08 mm and 3.97 ± 0.05 mm, respectively.

CONCLUSIONS

1. The results of odontometry for lower permanent molars in people with different dental arches have revealed a direct relationship between the teeth size (macrodontia, normodontia, microdontia) and their transversal (vestibular-lingual size of the crown, tooth neck and intertubercular distance), as well as the vertical (height of the vestibular, lingual odontomer and of the tubercle) parameters.
2. The obtained odontometric data can be used for diagnosing occlusive relationships and identifying various pathological, physiological abrasion types with varying degrees of occlusal surface loss.
3. The morphometric features of the teeth transverse and vertical parameters can offer meaningful data and be clinically significant in terms of diagnosing and predicting the course of the disease, as well as they are of reasonable scientific value and can be employed to clarify the mechanisms

REFERENCES

1. SHKARIN V.V., DOMENYUK D.A., LEPILIN A.V., FOMIN I.V., DMITRIENKO S.V. Odontometric indices fluctuation in people with physiological occlusion // *Archiv EuroMedica*, 2018. Vol. 8; 1. P. 12–18. <https://doi.org/10.35630/2199-885X/2018/8/1/12>
2. GORELIK E.V., DMITRIENKO S.V., IZMAYLOVA T.I., KRAYUSHKIN A.I. Features of the craniofacial complex in different age periods // *Morphology*. 2006. № 4. P. 39.
3. KOROBKEEV A. A., DOMENYUK D. A., SHKARIN V. V., DMITRIENKO S. V., MAZHAROV V. N. Variability of odontometric indices in the aspect of sexual dimorphism. *Medical News of North Caucasus*. 2019;14(1.1):103–107. DOI – <https://doi.org/10.14300/mnnc.2019.14062> (In Russ.)
4. DAVYDOV B.N., DOMENYUK D.A., DMITRIENKO S.V., KOROBKEEV A.A., ARUTYUNOVA A.G. Morphological peculiarities of facial skelet structure and clinical and diagnostic approaches to the treatment of dental anomalies in children in the period of early change. *Pediatric dentistry and prophylaxis*. 2019; Vol. 19; 1 (69): 26–38. (In Russ.) DOI: 10.33925/1683-3031-2019-19-69-26-38
5. DOMENYUK D.A., DAVYDOV B.N. Possibilities of microcomputer tomography in the diagnostics of early forms of caries of a chewing surface of permanent molars in children. Part I. *Pediatric dentistry and prophylaxis*. 2018; Vol. 18; 4 (67): 61–64. (In Russ.) DOI: 10.25636/PMP.3.2018.4.12
6. DOMENYUK D. A., CHUKOV S. Z., ARUTYUNOVA A. G., IVANYUTA O. O., ESAULENKO E. E., DMITRIENKO S. V. Evaluation of the caries resistance of tooth enamel according to a study on the chemical composition and microstructure of the tooth surface during its physiological maturation. *Kubanskii Nauch-*

- nyi Meditsinskii Vestnik. 2019; 26(2): 26–41. (In Russ., English abstract). <https://doi.org/10.25207/1608-6228-2019-26-2-26-41>
7. **DMITRIENKO S.V., DOMENYUK D.A., VEDESHINA E.G.** Shape individualization in lower dental arches drawn on basic morphometric features // *Archiv EuroMedica*, 2015. Vol. 5; 1. P. 11.
 8. **DMITRIENKO S.V., DOMENYUK D.A., KOCHKONYAN A.S., KARSLIEVA A.G., DMITRIENKO D.S.** Interrelation between sagittal and transversal sizes of maxillary dental arches // *Archiv EuroMedica*, 2014. Vol. 4; 2. P. 10–13.
 9. **DOMENYUK D.A., VEDESHINA E.G., DMITRIENKO S.V.** Correlation of dental arch major linear parameters and odontometric indices given physiological occlusion of permanent teeth in various face types // *Archiv EuroMedica*. 2016. Vol. 6; 2. P. 18–22.
 10. **PORFYRIADIS M.P., DOMENYUK D.A., DAVYDOV B.N., DMITRIENKO S.V., BUDAYCHIEV G.M.-A.** Variability of cephalometric indices in men and women with mesocephalic form of the head and various constitutional types of face (Part III). *The Dental Institute*. 2018; 80(3): 84–87. (In Russ.).
 11. **DMITRIENKO S.V., LEPILIN A.V., FOMIN I.V., DOMENYUK D.A., DAVYDOV B.N.** Study of morphology, methods of comparison of tooth and alveolar arcs by results of anthropometry and cellular-beam computer tomography (Part II). *The Dental Institute*. 2018; 80(3): 70–74. (In Russ.).
 12. **DOMENYUK D.A., DAVYDOV B.N., DMITRIENKO S.V., LEPILIN A.V., FOMIN I.V.** Diagnostic opportunities of cone-beam computer tomography in conducting craniomorphological and craniometric research in assessment of individual anatomical variability (Part I). *The Dental Institute*. 2018; 81(4): 52–55. (In Russ.).
 13. **DOMENYUK D.A., DAVYDOV B.N., DMITRIENKO S.V., LEPILIN A.V., FOMIN I.V.** Diagnostic opportunities of cone-beam computer tomography in conducting craniomorphological and craniometric research in assessment of individual anatomical variability (Part II). *The Dental Institute*. 2019; 82(1): 72–76. (In Russ.).
 14. **DMITRIENKO S.V., DOMENYUK D.A., KOCHKONYAN A.S., KARSLIEVA A.G., DMITRIENKO D.S.** Modern classification of dental arches // *Archiv EuroMedica*, 2014. Vol. 4; 2. P. 14–16.
 15. **DOMENYUK D.A., SHKARIN V.V., PORFYRIADIS M.P., DMITRIENKO D.S., DMITRIENKO S.V.** Classification of facial types in view of gnathology // *Archiv EuroMedica*, 2017. Vol. 7; 1. P. 8–13.
 16. **DMITRIENKO S.V., LEPILIN A.V., FOMIN I.V., DOMENYUK D.A., DAVYDOV B.N.** Study of morphology, methods of comparison of tooth and alveolar arcs by results of anthropometry and cellular-beam computer tomography (Part I). *The Dental Institute*. 2018; 79(2): 68–72. (In Russ.).
 17. **PORFYRIADIS M.P., DOMENYUK D.A., DAVYDOV B.N., DMITRIENKO S.V., BUDAYCHIEV G.M.-A.** Variability of cephalometric indices in men and women with mesocephalic form of the head and various constitutional types of face (Part II). *The Dental Institute*. 2018; 79(2): 82–85. (In Russ.).
 18. **DMITRIENKO S.V., DOMENYUK D.A.** Dentoalveolar specifics in children with cleft palate during primary occlusion period. *Archiv EuroMedica*, 2018; Vol. 8; 1: 33–34.
 19. **PORFYRIADIS M.P., DOMENYUK D.A., DAVYDOV B.N., DMITRIENKO S.V., BUDAYCHIEV G.M.-A.** Variability of cephalometric indices in men and women with mesocephalic form of the head and various constitutional types of face (Part I). *The Dental Institute*. 2018; 78(1): 70–73. (In Russ.).
 20. **DOMENYUK D.A., VEDESHINA E.G., DMITRIENKO S.V.** Mistakes in Pont (Linder-Hart) method used for diagnosing abnormal dental arches in transversal plane // *Archiv EuroMedica*. 2016. Vol. 6; 2. P. 23–26.
 21. **BORODINA V.V., DOMENYUK D.A., WEISHEIM L.D., DMITRIENKO S.V.** Biometry of permanent occlusion dental arches – comparison algorithm for real and design indicators // *Archiv EuroMedica*. 2018. Vol. 8; 1. P. 25–26. <https://doi.org/10.35630/2199-885X/2018/8/1/25>
 22. **DOMENYUK D.A., LEPILIN A.V., FOMIN I.V., DMITRIENKO S.V., BUDAYCHIEV G.M.-A.** Improving odontometric diagnostics at jaw stone model examination // *Archiv EuroMedica*. 2018. Vol. 8. № 1. P. 34–35.
 23. **DAVYDOV B.N., DOMENYUK D.A., DMITRIENKO S.V., KOROBKEEV A.A., ARUTYUNOVA A.G.** Morphological peculiarities of facial skeleton structure and clinical and diagnostic approaches to the treatment of dental anomalies in children in the period of early change. *Pediatric dentistry and prophylaxis*. 2019; Vol. 19; 1 (69): 26–38. (In Russ.) DOI: 10.33925/1683-3031-2019-19-69-26-38
 24. **DOMENYUK D.A., DAVYDOV B.N.** Possibilities of microcomputer tomography in the diagnostics of early forms of caries of a chewing surface of permanent molars in children. Part I. *Pediatric dentistry and prophylaxis*. 2018; Vol. 18; 4 (67): 61–64. (In Russ.) DOI: 10.25636/PMP3.2018.4.12
 25. **DMITRIENKO T.D., DOMENYUK D.A., PORFYRIADIS M.P., ARUTYUNOVA A.G., KONDRATYUK A.A., SUBBOTIN R.S.** Connection between clinical and radiological torque of medial incisor at physiological occlusion // *Archiv EuroMedica*. 2019. Vol. 9. № 1. P. 29–37. <https://doi.org/10.35630/2199-885X/2019/9/1/29>
 26. **PORFYRIADIS M.P., DOMENYUK D.A., ARUTYUNOVA A.G., DMITRIENKO S.V.** Scanning electron microscopy and X-ray spectral microanalysis in dental tissue resistance // *Archiv EuroMedica*. 2019. Vol. 9; 1: 177–185. <https://doi.org/10.35630/2199-885X/2019/9/1/177>
 27. **SHKARIN V.V., DOMENYUK D.A., PORFYRIADIS M.P., DMITRIENKO D.S., DMITRIENKO S.V.** Mathematical and graphics simulation for individual shape of maxillary dental arch // *Archiv EuroMedica*, 2017. Vol. 7; 1. P. 60–65.

28. PORFIRIADIS M.P., DMITRIENKO S.V., DOMENYUK D.A., BUDAYCHIEV G.M-A. Mathematic simulation for upper dental arch in primary teeth occlusion // *Archiv EuroMedica*, 2018. Vol. 8; 1. P. 36–37.
29. ZELENSKY, V.A. INTEGRAL INDICATOR FOR ORTHODONTIC CAREQUALITY CONTROL / V.A. ZELENSKY, D.A. DOMENYUK, M.V. BATURIN, I.V. ZELENSKY, A.V. KOKAREVA, A.V. ZENINA // *Medical news of North Caucasus*. 2014. – Vol. 9. – № 1. – P. 80–83. (In Russ., English abstract). DOI: 10.14300/mnnc.2014.09022.
30. LEPILIN A.V., FOMIN I.V., DOMENYUK D.A., DMITRIENKO S.V., BUDAYCHIEV G.M-A. Diagnostic value of cephalometric parameters at graphic reproduction of tooth dental arches in primary teeth occlusion // *Archiv EuroMedica*, 2018. Vol. 8; 1. P. 37–38. <https://doi.org/10.35630/2199-885X/2018/8/1/37>
31. SHKARIN V.V., PORFIRIADIS M.P., DOMENYUK D.A., DMITRIENKO D.S., DMITRIENKO S.V. Setting reference points for key teeth location in case of abnormal dental arch shape // *Archiv EuroMedica*. 2017. Vol. 7; 2. P. 111–117.
32. DOMENYUK D.A., DMITRIENKO S.V. PORFYRIADIS M.P. Major telerehthengogram indicators in people with various growth types of facial area // *Archiv EuroMedica*. 2018. Vol. 8; 1. P. 19–24. <https://doi.org/10.35630/2199-885X/2018/8/1/19>
33. DOMENYUK D.A., ZELENSKY V.A., RZHEPAKOVSKY I.V., ANFINOGENOVA O.I., PUSHKIN S.V. Application of laboratory and x-ray general studies un early diagnostics of metabolic disturbances of bone tissue in children with autoimmune diabetes mellitus. *Entomology and Applied Science Letters*. 2018; 5(4): 1–12.
34. DOMENYUK D.A., KONNOV V.V., PICHUGINA E.N., ANFINOGENOVA O.I., GONCHARENKO A.N., PUSHKIN S.V. Microcomputed tomography in qualitative and quantitative evaluation of dental enamel demineralization. *Entomology and Applied Science Letters*. 2018; 5(4): 72–83.
35. DAVYDOV B.N., DOMENYUK D.A., DMITRIENKO S.V. Peculiarities of microcirculation in periodont tissues in children of key age groups sufficient type 1 diabetes. Part I. *Periodontology*, 2019; Vol. 24; 1–24(90): 4–10. DOI: 10.25636/PMP.1.2019.1.1
36. DAVYDOV B.N., DOMENYUK D.A., DMITRIENKO S.V. Peculiarities of microcirculation in periodont tissues in children of key age groups sufficient type 1 diabetes. Part II. *Periodontology*, 2019; Vol. 24; 2–24(91): 108–119. DOI: 10.33925/1683-3759-2019-24-2-108-119
37. DAVYDOV B.N., DOMENYUK D.A., BYKOV I.M., IVCHENKO L.G., DMITRIENKO S.V. Modern possibilities of clinical-laboratory and x-ray research in pre-clinical diagnostics and prediction of the risk of development of periodontal in children with sugar diabetes of the first type. Part I. *Periodontology*, 2018; Vol. 23; 3–23(88): 4–11. DOI:10.25636/PMP.1.2018.3.1
38. DOMENYUK D.A., DAVYDOV B.N., DMITRIENKO S.V., SUMKINA O.B., BUDAYCHIEV G. M-A. Changes of the morphological state of tissue of the paradontal complex in the dynamics of orthodontic transfer of teeth (experimental study). *Periodontology*, 2018; Vol. 23; 1–23(86): 69–78. DOI:10.25636/PMP.1.2018.1.15
39. DOMENYUK D.A., ZELENSKY V.A., DMITRIENKO S.V., ANFINOGENOVA O.I., PUSHKIN S.V. Peculiarities of phosphorine calcium exchange in the pathogenesis of dental caries in children with diabetes of the first type // *Entomology and Applied Science Letters*. 2018. Vol. 5. № 4. P. 49–64.
40. KOROBKEEV A.A., DOMENYUK D.A., SHKARIN V.V., DMITRIENKO S.V. Types of facial heart depth in physiological occlusion. // *Medical news of North Caucasus*. 2018. – Vol. 13. – № 4. – P. 627–630. (In Russ., English abstract). DOI – <https://doi.org/10.14300/mnnc.2018.13122>.
41. KOROBKEEV A.A., DOMENYUK D.A., SHKARIN V.V., DMITRIENKO S.V., WEISHEIM L.D., KONNOV V.V. Anatomical features of the interdependence of the basic parameters of the dental arches of the upper and lower jaws of man. *Medical news of North Caucasus*. 2018. – Vol. 13. – № 1–1. – P. 66–69. (In Russ., English abstract). DOI – <https://doi.org/10.14300/mnnc.2018.13019>
42. DMITRIENKO S.V., DOMENYUK D.A., FISCHER S.B., SUBBOTIN R.S. Dynamics of periodontal fixing capacity through orthodontic treatment employing edgewise technique // *Archiv EuroMedica*. 2019. Vol. 9; 1: 151–152. <https://doi.org/10.35630/2199-885X/2019/9/1/151>
43. DMITRIENKO S.V., DOMENYUK D.A., PUZDYRYOVA M.N. Manufacturing methods for individual aligners and trainers from thermoplasts and clinical indications for their application // *Archiv EuroMedica*. 2019. Vol. 9; 1: 153–154. <https://doi.org/10.35630/2199-885X/2019/9/1/153>
44. LEPILIN A.V., RAJGORODSKIY YU.M., GRIGORYEVA D.A., EROKINA N.L., BAKHTEEVA G.R., DOMENYUK D.A. Reasoning for the application of violet laser physiotherapy device following surgeries in the oral cavity. *Archiv EuroMedica*, 2018; 8(2): 111–114.
45. DOMENYUK D.A., SHKARIN V.V., PORFIRIADIS M.P., DMITRIENKO D.S., DMITRIENKO S.V. Algorithm for forecasting the shape and size of dent arches front part in case of their deformations and anomalies // *Archiv EuroMedica*, 2017. Vol. 7. № 2. P. 105–110.
46. DMITRIENKO S.V., DAVYDOV B.N., V.V. SHKARIN, DOMENYUK D.A. Algorithm for determining the size of artificial teeth by the morphometric parameters of the face in people with full adentia. *Dentistry*. 2018; 97(6): 57–60. DOI – 10.17116/stomat20189706157
47. DMITRIENKO S.V., PORFIRIADIS M.P., DOMENYUK D.A., BUDAYCHIEV G.M-A. Dentoalveolar specifics in children with cleft palate during primary occlusion period // *Archiv EuroMedica*, 2018. Vol. 8. № 1. P. 33–34.

48. **SHKARIN V.V., DAVYDOV B.N., DOMENYUK D.A., DMITRIENKO S.V.** Non-removable arch orthodontic appliances for treating children with congenital maxillofacial pathologies – efficiency evolution // *Archiv EuroMedica*, 2018. Vol. 8. № 1. P. 97–98.
49. **FISCHEV S.B., PUZDYRYOVA M.N., DMITRIENKO S.V., DOMENYUK D.A., KONDRATYUK A.A.** Morphological features of dentofacial area in peoples with dental arch issues combined with occlusion anomalies // *Archiv EuroMedica*. 2019. Vol. 9; 1: 162–163. <https://doi.org/10.35630/2199-885X/2019/9/1/162>
50. **DMITRIENKO S.V., FOMIN I.V., DOMENYUK D.A., KONDRATYUK A.A., SUBBOTIN R.S.** Enhancement of research method for spatial location of temporomandibular elements and maxillary and mandibular medial incisors // *Archiv EuroMedica*. 2019. T. 9. № 1. P. 38–44. <https://doi.org/10.35630/2199-885X/2019/9/1/38>
51. **LEPILIN A.V., DMITRIENKO S.V., DOMENYUK D.A., PUZDYRYOVA M.N., SUBBOTIN R.S.** Dependence of stress strain of dental hard tissues and periodontal on horizontal deformation degree // *Archiv EuroMedica*. 2019. Vol. 9; 1: 173–174. <https://doi.org/10.35630/2199-885X/2019/9/1/173>
52. **DMITRIENKO S.V., KRAYUSHKIN A.I., DMITRIENKO D.S., EFIMOVA E.YU.** Topographic-anatomical features of the structure of the bone tissue of the mandibular segments // *Dentistry*. 2007. Vol. 86. № 6. P. 10–12.
53. **DOMENYUK D.A., VEDESHINA E.G., DMITRIENKO S.V.** Efficiency evaluation for integrated approach to choice of orthodontic and prosthetic treatments in patients with reduced gnathic region // *Archiv EuroMedica*. 2015. Vol. 5. № 2. P. 6–12.
54. **DMITRIENKO S.V., LEPILIN A.V., DOMENYUK D.A., KONDRATYUK A.A.** Clinical meaning of methods for identifying variability of mental prominence location // *Archiv EuroMedica*. 2019. Vol. 9; 1: 45–46. <https://doi.org/10.35630/2199-885X/2019/9/1/45>
55. **DOMENYUK D.A., PORFYRIADIS M.P., BUDAYCHIEV G. M-A.** Contemporary methodological approaches to diagnosing bone tissue disturbances in children with type 1 diabetes. *Archiv EuroMedica*, 2018; 8(2): 71–81.